

Effect of *Hypericum Perforatum* on Gastric Ulcer in Rat

Ali M.Hussein¹, Nadir Nanakali² Mohammed M.Hussein³

¹Department of Biomedical Sciences, Cihan University-Erbil, Kurdistan Region, Iraq, ali.m.hussein@cihanuniversity.edu.iq

²Department of Biology, College of Education, Salahaddin University, Kurdistan Region, Iraq, nadir.nanakali@su.edu.krd

³Near East University, Nicosia, North Cyprus/Turkey, mohammedmhussein98@gmail.com

Abstract:

Gastric ulcer is a chronic condition that occurs when the mucosa of the stomach is broken. There is a physiological equilibrium between aggressive factors and mucosal defense. This study aimed to determine the prevention level and efficiency of herbal medicinal plants (*Hypericum perforatum*) and compared with the omeprazole drug.

Many groups were prepared from Albino male rats, first control group (inoculate with *H. pylori* and fed with standard pellet), Second group, rats inoculated by *H. pylori* and prevented with aqueous extract *H. perforatum* in two dosages (250mg/kg, 500mg/kg), Third group inoculated by *H. pylori* and prevented with standard drug omeprazole at the dose (20mg/kg).

The result showed that *H. perforatum* inhibits (50.65%) stomach ulcer formation with a high dose. Omeprazole's group results showed (24.50%) stomachs ulcer formation. Although the result of the current study improves, a high dosage of aqueous extracts of plants has more effectiveness than the low dosage of aqueous extracts of plants.

Index Terms—gastric ulcer, *Helicobacter pylori*, antibacterial activity, gastrointestinal tract, peptic ulcer.

I. INTRODUCTION

Helicobacter Pylori is a highly motile, spiral-shaped and gram negative bacterium that colonizes the intestine of 50-80% of individuals around the world (1). *Helicobacter pylori*, usually in the form of gastritis, peptic ulcer disease, or also gastric malignancy, is a bacterium that causes damage to the gastric mucosa (2).

Gastric ulcer is a condition of the stomach lining that has common symptoms such as vomiting, burning, dull abdominal

pain, headache, weight loss, low oral resistance, stenosis, perforation and stomach bleeding (3).

Medicinal Plant The focus has been on natural plants, partially because certain pharmaceutical medicines are highly harmful to the patient or cause adverse effects. Moreover, in terms of cure and disease prevention, plant products are inexpensive and more affordable contributors to improving human health (4).

Hypericum Perforatum L. It belongs to the Hypericaceae and is generally referred to as St. John's Wort (SJW). It has been used as a treatment in various Eastern countries. Nevertheless, scholars suggest that it was used by ancient Greeks to cure mental illnesses that they felt involved demonic possession. In temperate open disturbed regions, it grows well (5).

Omeprazole is used for the treatment of conditions in which the stomach excretes large quantities of acid. It prevents the activity of a particular enzyme mechanism located within the acid-secreting stomach cells (in the stomach), thus preventing acid production. Omeprazole was being used to control: heartburn (heartburn), acute gastritis, duodenitis (duodenitis), esophagitis attributable to recurrence of gastrointestinal material, peptic ulcer and other secretory diseases.

Aim of study

The project's goal is to shown the effectiveness of *Hypericum perforatum*, and omeprazole in gastric ulcer in male albino rats was to decrease the ulcer size by using medicinal plants.

II. MATERIALS AND METHODS

Extraction of the Aerial Part of *H. perforatum*

Fresh aerial plants (Stem, Leaf, flower, fruit and seed) of *Hypericum perforatum* collected from Khabat (district of Erbil

city located in the west part of the Iraqi Kurdistan Region). Mainly the aerial part of the plant that has a high proportion of buds and flowers were used and collected in August 2020. The plant was air-dried indoors to protect it from direct sunlight.

A modified method described by (Ref 6) was used for the preparation of the aqueous extract of the fine powdered plant. The dried milled aerial parts at the rate of high dose (25g/250ml), Low dose (25g/500ml) mixed with distilled water (85°C), kept for (24h) and filtered with filter paper whatman No.1. Finally, the filtered extract was kept inside sterile cup in refrigerator until used.

Omeprazole

Omeprazole is the class of medicines that have been used to treat disorders including peptic ulcers as proton pump inhibitors. Omeprazole inhibits the acid forming enzymes in the stomach wall. The output of the stomach acid is reduced by blocking these enzymes and thus the stomach can be healed. Omeprazole was the reference anti-ulcer treatment in this sample and was extracted from (happy pharmacy) in Erbil city. The medication was supplied by mouth to rats at 20mg/kg body weight suspended in distilled water (5ml/kg) (7).

Experimental Animals

Forty eight male albino rats were used for the experiment, Rats body weight ranged from 160±20 gram 7-9 week old, the rats randomly allocated to four groups, each group of twelve rats were purchased from Zakho University, housed in well aerated cages under hygienic condition. The rats were fed on standart diet for one week in the animal house of the College of Education in the Salahaddin University-Erbil.

Induction of Gastric ulcer by *H. pylori*

Gastritis was induced by feeding rats with bacterium *Helicobacter pylori* that was collected from biopsy samples from clinical patient. The rats were fed on basal diet for one week in the animal house of the College of Education in the Salahaddin University-Erbil. In this study the rats were fasted in the morning and afternoon first inoculated by plant extracts then immediately inoculated with 1ml *H. pylori* suspension (5×10^8 - 5×10^{10} CFU/ml) by gavage twice daily at an interval of 4h for three consecutive days, then left on normal feeding for 15 days to seen the effect of the plants extracts with *H. pylori* activity (8), before inoculating animals with plants extract and *H. pylori* the animals do the antigen test via stool to ensure that did not infected with *H. pylori* before, In last period of prevention, anesthetized of the rats done by intramuscular injection of mixed xylazine-ketamine (1:9) as a single dose in the same syringe, The Stomach was removed of each rat from each group, then dissects the stomach (9).

Gross gastric lesions evaluation

Ulcers located in the gastric mucosa, parallel to the long stomach axis, emerged as elongated bands of hemorrhagic lesions. Thus the damage was studied in each gastric mucosa specimen, In the measurement of the ulcer region (UA), the total of the areas of all lesions for each stomach was added, wherein the sum of small squares $\times 4 \times 1.8 = UA \text{ mm}^2$ as previously defined by (Ref 9) with minor adjustment. The inhibition percentage (I %) was calculated by the following formula as described by (Ref10) with slight modification. (I %) = [(UA control – UA treated) ÷ UA control] $\times 100\%$ (10).

Measurement and evaluation of acid content of gastric juice (pH)

The pH level of stomach was individually recorded for evaluation the pH level of all groups of rats to know the effect and correlation of plant extract with pH level.

Microbiological analysis

Microbiological analysis directly carried out at the day of sample collection, Stool antigen and blood antibody test was done to all rats groups was analyzed by strip *H. pylori* antigen and antibody test to shown the rats infected with *Helicobacter pylori* or not.

III. RESULTS AND DISCUSSION:

Effect of Aqueous Extract of *Hypericum perforatum* and antibacterial omeprazole on Gross evaluation of gastric lesion

Table 1 Effect of Aqueous Extract of *Hypericum perforatum* and antibacterial Omeprazole of gastric ulcer production and inhibition the ulcer

Animal group	Prevention (5ml/kg) dose	Ulcer Area (mm ²) Mean \pm SEM	Ulcer Inhibition %
1	Ulcer control group	815.00	0
2	High dose <i>H. perforatum</i>	402.20	50.65
	Low dose <i>H. perforatum</i>	611.45	24.97
3	Omeprazole	615.25	24.50

The antiulcer activity of aqueous extract *H. Perforatum* against gastric lesion model caused by *H. pylori* is reported in Table 1. Results showed that ulcer area of rat's stomach with high dose (500mg/kg) of *H. Perforatum* extracts was inhibited at rate (50.65%) gastric ulcer formation compared with ulcer control group (11).

The antiulcer activity of omeprazole drug *H. pylori* induced gastric lesion model is shown in Table 1, Results showed that rats' stomach prevented with omeprazole with being given *H. pylori* solution reduced areas of gastric ulcer formation at rate (24.50%) ulcer area inhibition compared with gastric ulcer control group (12).

Evaluation of pH level of gastric content between *Hypericum perforatum* and antibacterial Omeprazole

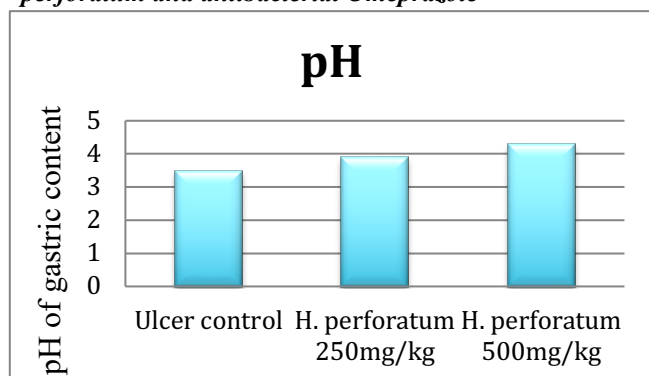


Fig.1. evaluation of pH level of gastric content between *Hypericum perforatum* and antibacterial Omeprazole

The acidity of gastric content in experimental animals prevented with *H. perforatum* was increased compared with that of the ulcer control group shown in Figure 1, The *H. perforatum* showed that the pH was between (4-4.5), while the acidity of gastric content in experimental animals prevented with omeprazole was increased compared with the ulcer control group, omeprazole showed that the pH was between (5-5.5) however control group pH level was at rate (3.5).

Evaluation of stomach color change in rats between *Hypericum perforatum* and antibacterial Omeprazole

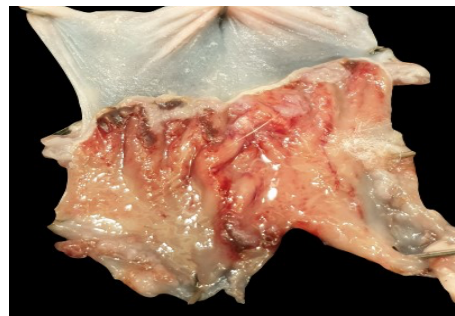
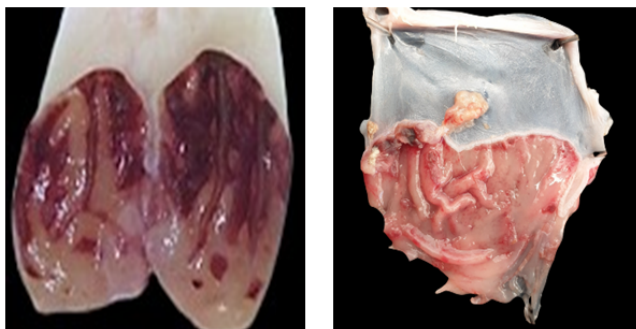
Fig.2. (a) shown the rats stomach control group, (b) rats stomach prevented with *H. perforatum* extract, (c) rats stomach prevented with antibacterial omeprazole.

The color of the stomach is one of the parameters that considered in the study, color of prevented rat stomach with *Hypericum perforatum* are significantly changed comparing with ulcer control group, white bright color was found in the stomach of the rats with *Hypericum perforatum*, pink to red color was found at the each of the stomach, otherwise the control groups stomach was totally dark red because of the ulcer and inflammation that caused by *H. pylori*, while the color of prevented rat stomach with omeprazole are changed comparing with ulcer control group, red bright color was found in the stomach of the rats with omeprazole shown in Figure 2 (13).

Gastritis is one of the most prominent clinical symptoms of *Helicobacter pylori* infection, *H. pylori* formed widely visible black hemorrhagic injuries on the stomach mucosa, Moreover this plant extraction had an effect at rate (50.65%) inhibition formation of stomach ulcers compared with control group in rats gastro-protective with the high dose plant extract of *H. perforatum* (500mg/kg) and 24.97% inhibition formation of the stomach ulcers in rats with low dose *H. perforatum* extract (250mg/kg), however another study result (14) were agrees with our study result finding that *H. perforatum* had effectiveness on gastro-protective in rat animal model, As an antibacterial agent, omeprazole, a standard drug used to treat gastric ulcers, plays a major role in preventing gastric ulcer disorders in a male albino rat animal model, that commonly caused by the *Helicobacter pylori*, According to the current study results, the stomach of mice treated with omeprazole infected with *H. pylori* showed a significant decrease in gastric ulcer formation sites at rate (24.50%) inhibition area compared to the ulcer control group. *H. pylori* solution produced widely visible black hemorrhagic lesions on the gastric mucosa (15).

Our study findings agrees with (16) that shown in 68 patients receiving concurrent non-steroidal anti-inflammatory drugs, the healing rates at four weeks were 61% in the group receiving 20 mg of omeprazole, significantly a great rate of

patients in the omeprazole groups were free of symptoms and ulcers. At 4th week healing rate was 61% in the group receiving omeprazole 20 mg, and a significant number of patients in the omeprazole group had no symptoms and ulcers (17, 18).

CONCLUSION

The present study demonstrated that stomach organ was prevented from *Helicobacter pylori* induction of gastric ulcer by the herbal plants. Also it showed the prevention of stomach epithelium with aqueous extract of *Hypericum perforatum*.

The following conclusions were drawn based on the outcomes of the present study:

1. Control group, induction of *Helicobacter pylori* without taking any plants or drug.
2. *Hypericum perforatum* group, prevented the stomach epithelium with two dosages (500,250 mg/ml) aqueous extract *Hypericum perforatum*, the results showed (50.65%) in high dose inhibition of ulcer area compared with control group, and (24.97%) in low dose inhibition of ulcer area.
3. Omeprazole drug group, the least effective on gastric epithelium was omeprazole at rate (24.50%) inhibit ulcer area compared with control group.

ACKNOWLEDGMENT

This project would not have been possible without the support of Sallahadin University-Erbil and Cihan University-Erbil by providing labs and equipment for researchers, all efforts and support are appreciated.

REFERENCES

1. Palamides, P., Jolaiya, T., Idowu, A., Loell, E., Onyekwere, C., Ugiagbe, R., & Carranza, M. (2020). *Helicobacter pylori* patient isolates from South Africa and Nigeria differ in virulence factor pathogenicity profile and associated gastric disease outcome. *Scientific Reports*, *10*(1), 1-13.
2. Yulizal, O. K., Lelo, A., Ilyas, S., & Raden, L. K. (2020). The effect of *Channa striata* extract and standard eradication regimen on asymmetric dimethylarginine in *Helicobacter pylori* gastritis rat model. *Veterinary World*, *13*(8), 1605.
3. Mashayekhi-sardoo, H., Razavi, B. M., Ekhtiari, M., Kheradmand, N., & Imenshahidi, M. (2020). Gastroprotective effects of both aqueous and ethanolic extracts of Lemon verbena leaves against indomethacin-induced gastric ulcer in rats. *Iranian Journal of Basic Medical Sciences*.
4. Youssef, H., & El-Mahmoudy, A. M. (2019). Evaluation of the antimicrobial potential of *Punica Granatum* leaves hydro-methanolic extract against selected pathogens. *American Journal of Current Microbiology*, *7*(1), 23-33.
5. Belwal, T., Devkota, H. P., Singh, M. K., Sharma, R., Upadhayay, S., Joshi, C., & Pande, V. (2019). St. John's Wort (*Hypericum perforatum*). In *Nonvitamin and Nonmineral Nutritional Supplements* (pp. 415-432).
6. HOSSEINI, V. S., Afzali, N., Namaei, M. H., & Allahressani, A. (2015). Effect of water extract of *Hypericum perforatum* on performance, abdominal fat and blood biochemical parameters of broiler chicken.
7. Pedernera, A. M., Guardia, T., Calderón, C. G., Rotelli, A. E., de la Rocha, N. E., Di Genaro, S., & Pelzer, L. E. (2006). Anti-ulcerogenic and anti-inflammatory activity of the methanolic extract of *Larrea divaricata* Cav. in rat. *Journal of ethnopharmacology*, *105*(3), 415-420.
8. Nasr, N. M., Khider, M., Metry, W., & Atallah, K. (2017). Antibacterial Activity of Lactic Acid Bacteria against *Helicobacter pylori* Evidence by in vivo and in vitro Studies. *Int. J. Curr. Microbiol. App. Sci*, *6*(12), 4235-4247.
9. Kauffman Jr, G. L., & Grossman, M. I. (1978). Prostaglandin and cimetidine inhibit the formation of ulcers produced by parenteral salicylates. *Gastroenterology*, *75*(6), 1099-1102.
10. Njar, V. C., Adesanwo, J. K., & Raji, Y. (1995). Methyl angolensate: the antiulcer agent of the stem bark of *Entandrophragma angolense*. *Planta medica*, *61*(01), 91-92.
11. Tanideh, N., Ghafari, V., Ebrahimi, R., Habibagahi, R., Koochi-Hosseinafshadi, O., & Iraj, A. (2020). Effects of *Calendula Officinalis* and *Hypericum Perforatum* on Antioxidant, Anti-Inflammatory and Histopathology Indices of Induced Periodontitis in Male Rats. *Journal of Dentistry*, *21*(4), 314-321.
12. Xie, L., Guo, Y. L., Chen, Y. R., Zhang, L. Y., Wang, Z. C., Zhang, T., & Wang, B. (2020). A potential drug combination of omeprazole and patchouli alcohol significantly normalizes oxidative stress and inflammatory responses against gastric ulcer in ethanol-induced rat model. *International immunopharmacology*, *85*, 106660.
13. Bessède, E., Arantes, V., Mégraud, F., & Coelho, L. G. (2017). Diagnosis of *Helicobacter pylori* infection. *Helicobacter*, *22*, e12404.
14. Zdunić, G., Gođevac, D., Milenković, M., Vučićević, D., Šavikin, K., Menković, N., & Petrović, S. (2009). Evaluation of *Hypericum perforatum* oil extracts for an antiinflammatory and gastroprotective activity in rats. *Phytotherapy Research*, *23*(11), 1559-1564.
15. Abdel-Salam, O. M. (2005). Anti-inflammatory, antinociceptive, and gastric effects of *Hypericum perforatum* in rats. *TheScientificWorldJOURNAL*, *5*.
16. Walan, A., Bader, J. P., Classen, M., Lamers, C. B., Piper, D. W., Rutgersson, K., & Eriksson, S. (1989). Effect of omeprazole and ranitidine on ulcer healing and relapse rates in patients with benign gastric ulcer. *New England Journal of Medicine*, *320*(2), 69-75.
17. Birkmann, K., Junge, H. K., Maischberger, E., Wehrli Eser, M., & Schwarzwald, C. C. (2014). Efficacy of omeprazole powder paste or enteric-coated formulation in healing of gastric ulcers in horses. *Journal of veterinary internal medicine*, *28*(3), 925-933.
18. Bush, J., Van Den Boom, R., & Franklin, S. (2018). Comparison of aloe vera and omeprazole in the treatment of equine gastric ulcer syndrome. *Equine veterinary journal*, *50*(1), 34-40.