

Cold-Induced Pediatric Acute Abdomen

Hazim A. Alhiti¹

¹ M.D-Al-Ramadi Teaching Hospital

Higher Institute of Health, Al Anbar Directorate of Health

Iraq

Abstract— Cold causes physiological bodily changes. This report of acute abdomen in Iraqi children exposed to the cold. This is a prospective research. This prospective research encompassed 245 Iraqi kids who experienced "acute abdomen" presented to my clinic over the winter seasons of 2019-2023. They all had exposed to cold with upper respiratory tract symptoms then suffered from abdominal pain for 12 hours. After obtaining informed consent, he clinically examined them, ordered investigations, and monitored the kids accordingly. Statistical analysis used: excel 2010. Out of 245 Iraqi kids, 156 were girls (63.7%) and 89 boys (36.3 %). Ultrasound expressed mesenteric lymph nodes in 142 girls (57.9%), but in 14 girls were not (5.6%). Leukocytosis was detected in 21 boys (8.4%), whereas 68 boys were not (27.6%). Conservative management was successful in 143 girls (58.6%) and 71 boys (28.9%), while surgery was effective in 14 girls (5.6%) and 17 boys (6.9%). Cold can induce "acute abdomen" in children, particularly during the winter months. Many children need careful observation and regular checkups.

Index Terms— abdominal pain, cold induced, Hit, pediatric.

I. INTRODUCTION

An acute abdomen is defined as sudden and severe abdominal pain that indicates a medical emergency requiring rapid diagnosis and treatment. Appendicitis, pancreatitis, intestinal blockage, or a ruptured organ are all potential causes. ¹ Acute abdomen signify a medical emergency that demands immediate diagnosis and treatment since it may indicate a dangerous and perhaps fatal condition. The urgency of diagnosing and treating acute abdomen stems from the risk of major, life-threatening consequences if not treated soon. ²

The effects of cold on the human body vary based on temperature, duration of exposure, wind chill, and individual sensitivity. ³ Cold exposure can cause hypothermia, frostbite, chilblains, trench foot, urticarial, respiratory troubles, cardiovascular consequences, seasonal affective disorder, and worsen symptoms of despair and anxiety. ⁴ Cold temperatures do not produce acute abdomen, but might indirectly lead to illnesses such as acute abdomen. Cold temperatures can produce vasoconstriction, which can restrict blood flow to the abdominal organs and result in disorders like ischemia or infarction, which can cause significant stomach discomfort. ⁵

Cold temperatures can cause muscular contraction and cramping. Cold exposure may aggravate symptoms and cause an abrupt flare-up of stomach discomfort in people who have pre-existing gastrointestinal illnesses such as inflammatory bowel disease ⁶. This study investigated the effects of cold on acute abdomen in a sample of Iraqi pediatric age group.

II. SUBJECTS AND METHODS

This is a prospective research that encompassed 245 Iraqi kids who experienced "acute abdomen" presented to my clinic in Al Anbar provenance over the winter seasons of 2019-2023. They all had upper respiratory tract symptoms then suffered from severe cramping or colicky abdominal pain for 12 hours.

The parents brought their kid to the surgical consultation, fearful of and/or recommended by a pediatrician, for suspicion of acute appendicitis. All parents verified that the child had cold exposure (in cold weather) or slept right beneath the cold split air conditioner (in hot weather). After obtaining informed consent and obscuring their identities, the researcher (a general surgeon specialized M.D) collected a full history of the kid and their partners before clinically examining them and ordering an "ultrasound, complete blood picture, and urine test".

The researcher monitored the kids accordingly and utilized Excel 2010 for the data. The author left out children and families who refused to be included.

III. RESULTS

Out of 245 Iraqi kids, 156 were girls (63.7%) and 89 boys (36.3 %). Ultrasound expressed mesenteric lymph nodes in 142 girls (57.9%), but in 14 girls were not (5.6%). Leukocytosis was detected in 21 boys (8.4%), whereas 68 boys were not (27.6%). Conservative management was successful in 143 girls (58.6%) and 71 boys (28.9%), while surgery was effective in 14 girls (5.6%) and 17 boys (6.9%).

TABLE. 1
THE GENDER DISTRIBUTION IN THIS RESEARCH. N=245.

| Age | Boys | Girls | Total |
|-------|-------------|--------------|-------------|
| 6-8 | 40 (16.3 %) | 59 (24.1 %) | 99 (40.4 %) |
| 9-10 | 31 (12.6 %) | 53 (21.7 %) | 84 (34.3 %) |
| 11-12 | 18 (7.4 %) | 44 (17.9 %) | 62 (25.3 %) |
| Total | 89 (36.3 %) | 156 (63.7 %) | 245 (100 %) |

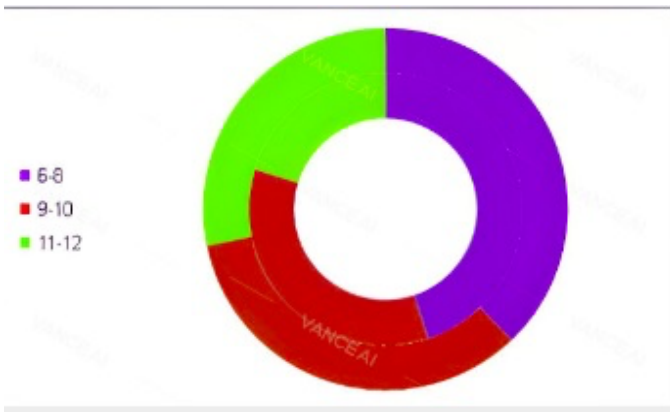


Fig. 1. The gender distribution in this research. N=245.

TABLE. II
THE SAMPLE IS ARRANGED BASED ON THE PRESENCE OF MESENTERIC LYMPH NODES DETECTED BY ULTRASOUND. N= 245.

| | Boys | | Girls | | Total |
|-------|-------------|------------|--------------|------------|-------------|
| | Detected | Not | Detected | Not | |
| 6-8 | 38 (15.5 %) | 2 (0.8 %) | 55 (22.5 %) | 4 (1.6 %) | 99 (40.4 %) |
| 9-10 | 27 (11 %) | 4 (1.6 %) | 48 (19.4 %) | 5 (2 %) | 84 (34.3 %) |
| 11-12 | 13 (5 %) | 5 (2 %) | 39 (16 %) | 5 (2 %) | 62 (25.3 %) |
| Total | 78 (31.5 %) | 11 (4.4 %) | 142 (57.9 %) | 14 (5.6 %) | 245 (100 %) |

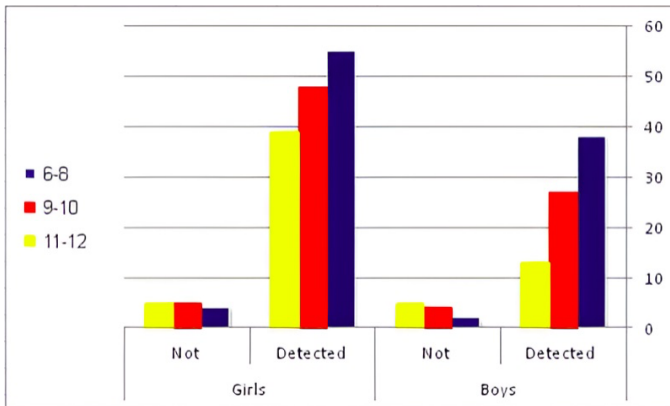


Fig. 2. The sample is arranged based on the presence of mesenteric lymph nodes detected by ultrasound. N= 245.

TABLE. III
THE GENDER ARRANGEMENT BASED ON THE PRESENCE OF LEUCOCYTOSIS IN THE LABORATORY TEST. N= 245.

| | Boys | | Girls | | Total |
|-------|--------------|-------------|--------------|--------------|-------------|
| | Leukocytosis | Not | Leukocytosis | Not | |
| 6-8 | 5 (2 %) | 35 (14.3 %) | 7 (2.8 %) | 52 (21.3 %) | 99 (40.4 %) |
| 9-10 | 7 (2.8 %) | 24 (9.7 %) | 10 (4 %) | 43 (17.8 %) | 84 (34.3 %) |
| 11-12 | 9 (3.6 %) | 9 (3.6 %) | 13 (5.8 %) | 31 (12.3 %) | 62 (25.3 %) |
| Total | 21 (8.4 %) | 68 (27.6 %) | 30 (12.6 %) | 126 (51.4 %) | 245 (100 %) |

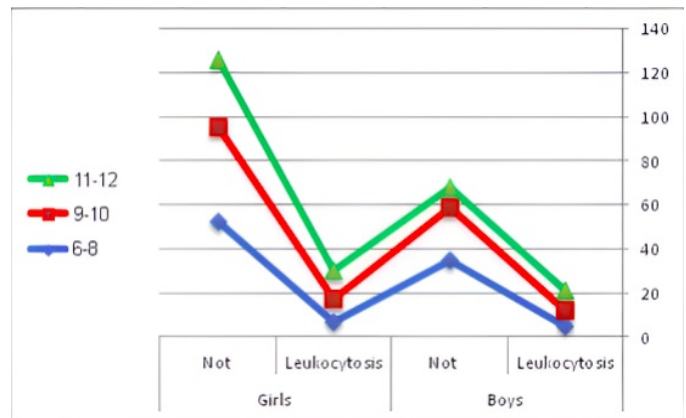


Fig. 3. The gender arrangement based on the presence of leucocytosis in the laboratory test. N= 245.

TABLE. IV
THE GENDER ARRANGEMENT BASED ON THE PRESENCE OF LEUKOCYTOSIS IN THE LABORATORY TEST. N= 245.

| | Boys | | Girls | | Total |
|-------|--------------|------------|--------------|------------|-------------|
| | Conservative | Surgery | Conservative | Surgery | |
| 6-8 | 36 (14.6 %) | 3 (1.2 %) | 58 (23.8 %) | 2 (0.8 %) | 99 (40.4 %) |
| 9-10 | 25 (10.3 %) | 6 (2.5 %) | 48 (19.5 %) | 5 (2 %) | 84 (34.3 %) |
| 11-12 | 10 (4 %) | 8 (3.2 %) | 37 (15.3 %) | 7 (2.8 %) | 62 (25.3 %) |
| Total | 71 (28.9 %) | 17 (6.9 %) | 143 (58.6 %) | 14 (5.6 %) | 245 (100 %) |

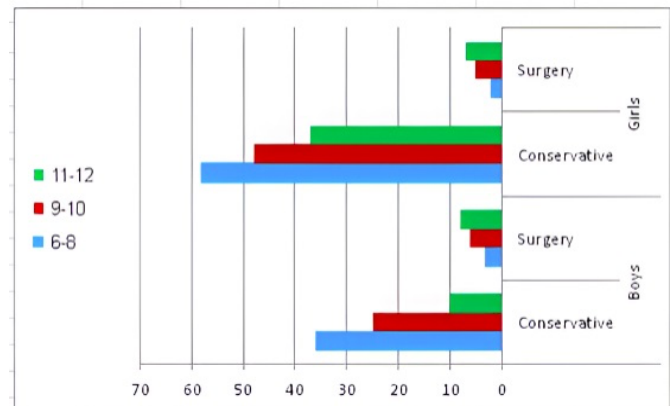


Fig. 4. The gender arrangement based on the presence of leucocytosis in the laboratory test. N= 245.

IV. DISCUSSION

An acute abdomen signifies a sudden and intense abdominal discomfort, indicating a medical emergency needing prompt diagnosis and treatment. Potential reasons include appendicitis, pancreatitis, intestinal obstruction, and organ rupture. This study looked at the effects of cold on acute

abdomen in a sample of Iraqi children.

This study included 245 Iraqi children, which is a medium sample to exhibit the consequences and draw conclusions, albeit it did not cover all provenances in Iraq as it is restricted to Heet City, a small district in Al Anbar provenance. The children had "acute abdomen" and visited my clinic throughout the winter seasons of 2019-2023.

All children experienced upper respiratory tract symptoms (within two days), as evidenced by their medical history and clinical examination, and their parents corroborated this by discussing their visit to an ENT specialist or pediatrician specialist.

For 12 hours, the encompassed children experienced severe cramping or colicky "acute abdomen". The parents took their child to the surgical consultation, terrified of and/or suggested by a pediatrician, for the possibility of acute appendicitis.

All parents verified that the child had cold exposure (in cold weather) or slept right beneath the cold split air conditioner (in hot weather). Well-know, exposure to cold temperatures might induce abdominal pain. Vasoconstriction leading to reduced blood flow to the area, or even gastrointestinal cramps. Iraqi heritage insisted that, it is important to keep the abdomen warm in cold weather to prevent abdominal discomfort.⁷

According to table and figure 1, there were 156 females (63.7%) and 89 boys (36.3%). This noteworthy finding revealed that acute abdomen was more common in boys in this study. Furthermore, younger children were more prevalent than others. This might be because girls are more sensitive to colder temperatures than guys. Furthermore, because of their lack of understanding and increased curiosity, younger children were more influenced by cold exposure than older children. This outcome went with several published materials in the nations.⁸

From table 2 and figure 2, The reader may observe that this research sample was sorted depending on the existence of mesenteric lymph nodes discovered by ultrasonography. The presence of mesenteric lymph nodes signifies Mesenteric lymphadenitis which is a disorder marked by inflammation and swelling of the mesenteric lymph nodes.⁹

Infections such as viral or bacterial gastroenteritis, appendicitis, or inflammatory bowel disease hide beneath the problem. Mesenteric lymphadenitis heals by the correct treatment.¹⁰

Mesenteric lymph nodes were detected by ultrasound in 142 girls (57.9%), but not in 14 girls (5.6%). This crucial conclusion is attributable to the physiology and anatomy of females. Again, the younger females were detected positively because to the sensitivity of the ultrasonography and the great role of immunity in the younger youngsters. These outcomes were consistent with world research.¹¹

While 78 boys had positive ultrasound detection of Mesenteric lymph nodes (31.5%), 11 boys did not (4.4%). The explanation is male physiology and anatomy, while the sensitivity of ultrasonography and the important function of immunity in early children provide the solution. These results went well with the established studies.¹²

According to table and figure 3, the witness might see that there were 126 girls did not express leukocytosis (51.4 %),

while 30 were positive (12.6 %). Viral infection is the sole explanation, but inflammatory bowel diseases or *Helicobacter Pylori* might still hidden.¹³

This is also applied to male children in which leukocytosis was detected in 21 boys (8.4%), whereas 68 boys were not (27.6%). These results went well with the established studies.¹⁴

According to table 4 and figure 4, conservative therapy was beneficial in 143 girls (58.6%) and 71 boys (28.9%), whereas surgery was effective in 14 girls (5.6%) and 17 boys (6.9%). These new findings back up the previously stated theories.¹⁵

Appendicitis (proven clinically, laboratory, and radiologically) can afflict persons of all ages, although it is more prevalent in children, making surgical removal of the appendix the best option for the remaining few children. These results went well with the established studies.¹⁶

Organizing surgical data is critical for delivering efficient and effective surgical treatment. Healthcare practitioners that keep accurate and conveniently available records may follow patient outcomes, assess patterns, and find areas for improvement. This allows them to make more educated treatment decisions, maintain patient safety, and improve overall healthcare quality.¹⁷

Healthcare personnel work relentlessly to give the best possible care to their patients. Surgeons, pediatricians, nurses, and other support workers collaborate to arrive at the best possible diagnosis.¹⁸ Iraq has the region's most developed health-care system, particularly in the recent decade.¹⁹ Iraqi health officials work hard to improve Iraq's health system and make it the finest in the area.²⁰

CONCLUSION

Cold can induce "acute abdomen" in children, particularly during the winter months. Many children may be treated with careful observation and regular checkup, with appendectomy being the final resort.

ACKNOWLEDGMENT

Use the singular heading even if you have many acknowledgments. Allah my god. The author acknowledged all the participant's families in this study.

REFERENCES

- Téoule, P. (2020). Acute Appendicitis in Childhood and Adulthood. *Dtsch Arztebl Int*, 6, 764-774. doi: 10.3238/arztebl.2020.0764
- Moris, D. (2021). Diagnosis and Management of Acute Appendicitis in Adults: A Review. *JAMA*, 14, 2299-2311. doi: 10.1001/jama.2021.20502
- Liu, Y. (2021). The Effects of a Passive Exoskeleton on Human Thermal Responses in Temperate and Cold Environments. *Int J Environ Res Public Health*, 8, 3881-3889. doi: 10.3390/ijerph18083889
- Søberg, S. (2021). Altered brown fat thermoregulation and enhanced cold-induced thermogenesis in young, healthy, winter-swimming men. *Cell Rep Med*, 11, 100402-100408. doi: 10.1016/j.xcrm.2021.100408

- Cui, P. (2022). Research on the Effects of Soundscapes on Human Psychological Health in an Old Community of a Cold Region. *Int J Environ Res Public Health*, 12, pp. 7212. doi: 10.3390/ijerph19127212
- Peng, Y. (2023). Effects and mechanisms of extremely cold environment on body response after trauma. *J Therm Biol*, 2023, 103564-103570. doi: 10.1016/j.jtherbio.2023.103570
- Al-Ali, A. (2011). Children's Exposure to Mildly Cold Environment. *IPMJ*, 10, 278-283. Retrieved from <https://www.iasj.net/iasj/article/42900>
- Brenner, D. (2023). Rare, Overlooked, or Underappreciated Causes of Recurrent Abdominal Pain: A Primer for Gastroenterologists. *Clin Gastroenterol Hepatol*, 21, 264-279. doi: 10.1016/j.cgh.2022.09.022
- Blevrakis, E. (2022). Mesenteric Lymphadenitis Presenting as Acute Abdomen in a Child with Multisystem Inflammatory Syndrome. *Infect Dis Rep*, 6, 428-432. doi: 10.3390/idr14030046
- Pavlovic, M. (2022). Efficacy of Prednisone in Children with Acute Nonspecific Mesenteric Lymphadenitis: A Pilot Study. *Acta Medica (Hradec Kralove)*, 65, 25-28. doi: 10.14712/18059694.2022.12
- Peng, X. (2022). Value of high frequency ultrasonography in differential diagnosis of mesenteric lymphadenitis and acute appendicitis in children. *Minerva Pediatr (Torino)*, 74, 389-391. doi: 10.23736/S2724-5276.21.06735-5
- Xu, X. (2022). Clinical Value of Abdominal Ultrasonography in the Diagnosis of Acute Abdomen in Children. *Contrast Media Mol Imaging*, 2022, 2681538-2681543. doi: 10.1155/2022/2681543
- Alhiti, H. (2022). The Impact of the Differential White Blood Cells in the Diagnosis of the Acute Right Iliac Fossa Pathology. *Biointer Resear in Appli Chemist*, 10, 6082 – 6087. DOI: 10.33263/BRIAC105.60826087
- Alhiti, H. (2020). Editorial Note for journal of emergency and trauma care. *Journ emerg trauma care*, 4, 1. Retrieved from https://www.researchgate.net/publication/357956967_Editorial_Note_for_Journal_of_Emergency_and_Internal_Medicine_IPJEIM#fullTextFileContent
- Alhiti, H. (2021). Alvarado Score in Surgical Skills. *IJCS*, 15, 525-527. Retrieved from https://www.researchgate.net/publication/354950192_Alvarado_Score_in_Surgical_Skills#fullTextFileContent
- Téoule, P. (2020). Acute Appendicitis in Childhood and Adulthood. *Dtsch Arztebl Int*, 6, 764-774. doi: 10.3238/arztebl.2020.0764
- Alhiti, H. (2021). Organizing Surgical Data Improves Surgical Care. *EJBI*, 17, 45-46. Retrieved from https://www.researchgate.net/publication/356415265_Organizing_surgical_data_improves_surgical_care
- Alhiti, H. (2021). The Surgical Healthcare Teams Fight against nCovid-19. *J Biol Today's World*, 10, 001. Retrieved from https://www.researchgate.net/publication/353924568_The_Surgical_Healthcare_Teams_Fight_against_nCovid-19
- Alhiti, H. (2022). Comparing Iraq and USA Health Systems: 2009-2019. *MJMS*, 1, 10. Doi: 10.55810/2789-9128.1011
- Alhiti, H. (2021). A Reviewing the Top Health Systems with Comparison to Iraqi Health System: Commercial Health Systems Review. *J Fac Med Bagdad*. 63, 43-9. Retrieved from <https://iqjmc.uobaghdad.edu.iq/index.php/19JFacMedBagdad36/article/view/1831>