


# A bitter flavonoid gum from *Dorema aucheri* accelerate wound healing in rats: Involvement of Bax/HSP 70 and hydroxyprolin mechanisms

Khaled Abdul-Aziz Ahmed<sup>1</sup> | Ahmed A.j. Jabbar<sup>2</sup>  | Mohammed M. Hussein M. Raouf<sup>3</sup> | Ayman M. Al-Qaaneh<sup>4</sup> | Ramzi A. Mothana<sup>5</sup> | Abdullah R. Alanzi<sup>5</sup> | Fuad Othman Abdullah<sup>6</sup> | Rawaz Rizgar hassan<sup>7</sup> | Mahmood Ameen Abdulla<sup>8</sup> | Musher Ismael Saleh<sup>9</sup> | Sidgi Hasson<sup>10</sup>

<sup>1</sup>Associate Professor at Department of Medical Laboratory Sciences, Faculty of Allied Medical Sciences, Al-Ahliyya Amman University, Amman, Jordan

<sup>2</sup>Department of Medical Laboratory Technology, Erbil Technical Health and Medical College, Erbil Polytechnic University, Erbil, Iraq

<sup>3</sup>Department of Biomedical Sciences, College of Applied Science, Cihan University-Erbil, Erbil, Kurdistan Region, Iraq

<sup>4</sup>Department of Allied Health Sciences, Al-Balqa Applied University (BAU), Al-Salt, Jordan

<sup>5</sup>Department of Pharmacognosy, College of Pharmacy, King Saud University, Riyadh, Saudi Arabia

<sup>6</sup>Department of Chemistry, College of Science, Salahaddin University-Erbil, Kurdistan Region, Erbil, Kurdistan Region, Iraq

<sup>7</sup>Department of Medical Laboratory Science, College of Science, Knowledge University, Erbil, Iraq

<sup>8</sup>Department of Medical Analysis, Faculty of Applied Science, Tishk International University, Erbil, Iraq

<sup>9</sup>Department of Chemistry, Faculty of Science and Health, Koya University, Koya KOY45, Erbil, Kurdistan Region, Iraq

<sup>10</sup>School of Pharmacy and Biomolecular Sciences, Liverpool John Moores University, Liverpool, UK

## Correspondence

Ahmed A.j. Jabbar, Department of Medical Laboratory Technology, Erbil Technical Health and Medical College, Erbil Polytechnic University, Erbil 44001, Iraq.  
Email: [ahmed.abuljabbar@epu.edu.iq](mailto:ahmed.abuljabbar@epu.edu.iq)

## Funding information

Researchers Supporting Project, Grant/Award Number: RSP2024R119; King Saud University

## Abstract

**Background:** *Dorema aucheri* gum (DAG) is a bitter flavonoid gum widely used for numerous medicinal purposes including wound recovery. The present work investigates the acute toxicity and wound-healing effects of DAG in excisional skin injury in rats.

**Materials and methods:** Sprague Dawley rats (24) were clustered into four groups, each rat had a full-thickness excisional dorsal neck injury (2.00 cm) and addressed with 0.2 mL of the following treatments for 15 days: Group A (vehicle), rats addressed with normal saline; Group B, rats received intrasite gel; C and D, rats addressed with 250 and 500 mg/kg of DAG, respectively.

**Results:** The results revealed the absence of any toxic signs in rats who received oral dosages of 2 and 5 g/kg of DAG. Wound healing was significantly accelerated following DAG treatments indicated by smaller open areas and higher wound contraction percentages compared to vehicle rats. Histological evaluation revealed higher fibroblast formation, collagen deposition, and noticeably lower inflammatory cell infiltration in

This is an open access article under the terms of the [Creative Commons Attribution-NonCommercial-NoDerivs](https://creativecommons.org/licenses/by-nc-nd/4.0/) License, which permits use and distribution in any medium, provided the original work is properly cited, the use is non-commercial and no modifications or adaptations are made.

© 2024 The Author(s). *Skin Research and Technology* published by John Wiley & Sons Ltd.

granulated skin tissues of DAG-addressed rats compared to vehicle rats. DAG treatment caused significant modulation of immunohistochemical proteins (decreased Bax and increased HSP 70) and inflammatory mediators (reduced TNF- $\alpha$ , IL-6, and magnified IL-10), which were significantly varied compared to vehicle rats. Moreover, topical DAG treatment led to significant upregulation of the hydroxyproline (HDX) (collagen) and antioxidant content. At the same time, decreased the lipid peroxidation (MDA) levels in healed tissues obtained from DAG-treated rats.

**Conclusion:** The present wound contraction by DAG might be linked with the modulatory effect of its phytochemicals (polysaccharides, flavonoids, and phenolic) on the cellular mechanisms, which justify their folkloric use and provokes further investigation as therapeutic drug additives for wound contraction.

#### KEYWORDS

anti-inflammatory, antioxidant, botanical, *Dorema aucheri*, wound healing

## 1 | INTRODUCTION

The human body is composed of various organs and skin is considered the largest one that constitutes a protective layer over the surface of our body. Skin is an immunological barrier that has numerous physiological and immunological functions including prevention of microbial penetration, lubrication, protection against ultraviolet light, fortifies mechanical pressure, vitamin production, pigmentation, preserves water and electrolytes in the normal range (regulates evapotranspiration), septicity, and sustains body temperature.<sup>1</sup> Human skin is composed of a complex structure made of an outer epidermal layer, middle dermal layer, and inner hypodermis layer containing subcutaneous tissues, along with appendages (hair follicles), sebaceous and sweat glands. The skin is increasingly vulnerable to various environmental objects that may cause skin injury, including burns, surgical incisions, and autoimmune defects, and trauma, which subsequently lead to chronic wounds or sever scars that may have serious consequences including psychological problems or even death.<sup>2</sup> The U.S. statistical data revealed that annual skin healthcare costs reaches ~\$50, 12\$, and \$7.5 billion for chronic wounds, scars, and burns, respectively. While in China, cost for chronic wound treatment is about \$8010 per capita in 2018.<sup>3</sup>

Skin wounds are an outcome of histological disruption of the skin tissues as a result of environmental or non-environmental factors or dysfunctionality in a particular skin layer, subsequently causing tissue irregularities. The wound's existence allows the penetration of various pathogenic molecules and microbes to enter the body and stimulate various immunological and inflammatory responses.<sup>3</sup> Microbial skin penetration can generate a local infection (inflammatory skin) or a systematic infection (septicemia), which becomes a serious risk factor for a deleterious health problem. Therefore, continuous search is crucial for finding a new effective method of wound management, which includes stopping bleeding, avoiding microbial infection, and facilitating the wound healing process without any side effects or deformities.<sup>4</sup>

Nowadays, the pharmaceutical industry provides numerous wound treatments for various wounds (acute and chronic), including plasma, gene, growth factors, and cell therapies, which chemical synthetics comprise only 1%–3% of Western Pharmacopoeia in contrast to almost 30% of plant-derived compounds used for wound management.<sup>5</sup> Natural products can exhibit significant healing potential in contracting various skin wounds and shorten periods required for the wound closure due to their physiological effects on various cellular processes associated with a faster wound contraction.<sup>6,7</sup>

Plants and their chemical products could become safe, inexpensive, and effective alternatives for acceleration of wound-healing due to their positive modulation of angiogenesis, collagen deposition, leukocyte infiltration, and the proliferation of epithelial cells.<sup>8</sup> Plant extracts have been prepared in different routes and used as traditional medicine for treating various wounds among nations.<sup>9,10</sup> Therefore, researchers extensively analyzed different plant extracts for their wound-contracting potentials. *Dorema aucheri* Boiss, as a folkloric herb, has been mentioned as ethnobotanical plant medicine for wound healing by numerous scientists surveying in Iraq, Iran, and Turkey.<sup>11–14</sup>

*Dorema aucheri* Boiss (Apiaceae family) is an endemic plant species and perennial plant that reaches a rosette stage for 3–4 years with one flowering stage.<sup>15</sup> *D. aucheri* are well distributed in the Hawraman region, southeast of Kurdistan (Iraqi Kurdistan), including areas, Tawella, Byara, Ahmadhawa (645 m a.s.l.), Ababayle, Eneb, and Hawar. The aerial parts of Bana (local name) boiled in soup or fried after boiling give an aromatic odor and a vague taste, which were utilized for various health purposes.<sup>11</sup> The gums (“gum ammoniac”) of Bilhar and Kaal (local name in southern regions of Iran) are collected from fresh stems (tear-form), which is white fluid becomes yellow viscous once exposed to air (average per plant 60 g); shoot incision, crushing of fresh stem before or during a thesis by a sharp knife to induce gum production, and collecting them a few days later (average per plant 100 g); shoot tapping, performed on thick root plants in which the leaves are

bent down and fixed on the ground by big rocks to prevent uprising of the gum and enhancing its buildup in the roots and then a few days later (3–4 days), top of roots were cut and gum was collected (average per plant 200 g).<sup>16</sup> The fresh paste or boiled gum of *D. ahcheri* is utilized as traditional therapy for asthma, expectorants, parasites of the digestive system, constipation, burn healing, and bronchitis.<sup>17</sup> Moreover, gums have been also utilized as anti-spasmodic, expectorants.<sup>18</sup> People in Kerman province, Iran, have applied *D. ahcheri* gums (local name: Eshterk, Shotork, Oshork) as a poultice for treating skin cracks, dried powder of gum were hammered, heated until became liquid, and applied on the skin wound for 3–4 days.<sup>16</sup>

Ammoniac gum exudates from stems of *D. aucheri* Bois, have shown numerous phytochemical compounds, including Cuparene,  $\beta$ -Funebrene,  $\alpha$ -Humulene, Barbatene, Germacrene D, Z-Ocimenone, Bisabolene, Amorpha-4,11-diene, and other chemicals belonging to phenolic, flavonoid classes.<sup>19</sup> The extracts from leaves, stems, and roots of *Dorema aucheri* Boiss showed significant antioxidant and antimicrobial potentials, which were linked with its chemical profiles, phenolic, flavonoid, caffeic acid, anthocyanin, carotenoid, chlorogenic acid, p-coumaric acid, soluble sugar, and gallic acid.<sup>20,21</sup> Phytochemical analysis by GC-MS technique revealed  $\beta$ -caryophyllene, cuparene, thymol,  $\beta$ -gurjunene, and carvacrol as major constituents of *D. aucheri* essential oils.<sup>22</sup> Moreover,  $\alpha$ -Eudesmol (31.2%) and  $\delta$ -cadinene (10.9%) were most abundant components of volatile oils obtained from *D. aucheri*.<sup>23</sup> The *D. aucheri* Boiss extracts (200 and 400 mg/kg) present significant anti-cancer potentials in DMBA-mediated breast tumors in rats, which were mainly linked with its flavonoid contents, mainly neptetine.<sup>24</sup> Moreover, phenolic content of aerial parts of *D. aucheri* Boiss extracts was mainly linked with its significant cytotoxic actions against numerous human cancer (breast, colorectal, breast, lung, and human cervical) cells.<sup>25</sup>

Despite numerous in vitro and in vivo literature, a conceived investigation to validate the safety and evaluate the wound healing potentials of ammoniac gum is absent, here, the present work designed to determine the wound healing actions of DAG on the dorsal neck-injured rats by histopathological, immunohistochemically, and biochemical assays.

## 2 | MATERIAL AND METHODS

### 2.1 | Ethic approval

The laboratory protocols regarding rats were based on the National scientific instructions for animal use.<sup>26</sup> The present animal study approved by the ethical committee of Applied Science College, Tishk international University (No.45, 22/01/2023).

### 2.2 | Chemicals

Ammoniac gum was bought commercially from a Qaesar market, Erbil, Kurdistan Region, Iraq (Figure 1). DAG was dissolved in 10% Tween 20 and preserved in dark bottles. The intrasite gel was bought from

Sigma Ald-rich, China, a reference drug contains polymer (2.3%), carboxymethyl cellulose (CMC), and propylene (20%).

### 2.3 | Acute toxicity trial

The toxicity trial was following guidelines recommended by OECD-423.<sup>27</sup> In brief, 36 Sprague Dawley rats (from both genders, weighted 180–200 g, and aged 7–8 weeks) were placed in three separated cages: Group A, rats had normal saline; group B, rats received single oral dosage of 2 g/kg DAG; group C, rats had single oral dosage of 5 g/kg DAG. Before treatment, all rats were fasted before and after treatment for 3–4 h. The observational procedure started after half hour of DAG delivery and the following 14 days for toxicity incidence (eye color, mild tremors, frightened, convulsion, and breathing problems) or mortality.

The physiology of all rats, including daily movements, respiration, skin piloerection, feed intake, salivation, and exophthalmus, was taken into consideration. On day 15th, all rats had an overdose of anesthesia containing 3 mg/kg xylazine and 30 mg/kg ketamine and then sacrificed. The dissected liver and kidneys were evaluated by histological assays and obtained blood samples were biochemically analyzed.<sup>28</sup>

### 2.4 | Wound healing experiment

#### 2.4.1 | Excision wound healing in rats

Sprague Dawley rats (24) were clustered randomly and equally separate into four steel cages and they were provided with food (diet pallet) and water for 1 week as standard adaptation procedure. After that, a small dose of anesthesia containing 3 mg/kg xylazine and 30 mg/kg ketamine was given to all rats to allow shaving dorsal neck area and rinsing with 70% alcohol. By using a sharp round seal, a unified circular dorsal cut (2.00 cm, diameter) was formed<sup>29</sup> (Figure 2). Then, they were treated twice daily with 0.2 mL of the following topical treatments: Group A rats treated with normal saline; Group B rats had intrasite gel; Group C rats received 250 mg/kg of DAG; D, rats had 0.2 mL of 500 mg/kg of DAG.

The closure area of skin cuts at different time periods (at 0, 5, 10, and 15 days after excision) was determined by highlighting it in square millimeters. The wound closure percentage was found using a highlighter, paper squares, and graph paper (1 mm<sup>2</sup>) once rats were partially anesthetized by intraperitoneal injections (0.1 mL/20 g). The calculation for the closure % included the following equation:

After final evaluation of skin cuts on day 15, all rats received an overdose of anesthesia and sacrificed. The skin samples were excised from all rats and taken into histopathology laboratory. The collected blood specimens were biochemically analyzed for different serum parameters.<sup>7</sup>

The processing of skin samples began with mixing them with phosphate (10%)-buffered formalin and transferred into tissue-processed machine for fixation, dehydration, paraffinization, clearing, and



**FIGURE 1** Commercial ammoniac gums in Local shop in Qaysari Market (A), Kurdistan region, Iraq (Taken by A.A.J.). Gums are available in liquid (B) and solid small random shaped granules (C) in small jars (D).

infiltration. After tissue fixation on glass slides and coloring with different stains (Masson's trichrome, hematoxylin, and eosin), the slides were incubated for overnight, and then, they were observed under light microscope (Nikon) for any plausible tissue changes, including infiltrated inflammatory cells, collagen deposition, fibroblast proliferation, neovascularization, and epithelialization.<sup>30,31</sup> The slides examined at a low 2× magnification to observe all fields of skin area by an histopathologist, after which it was increased by 100× magnification.

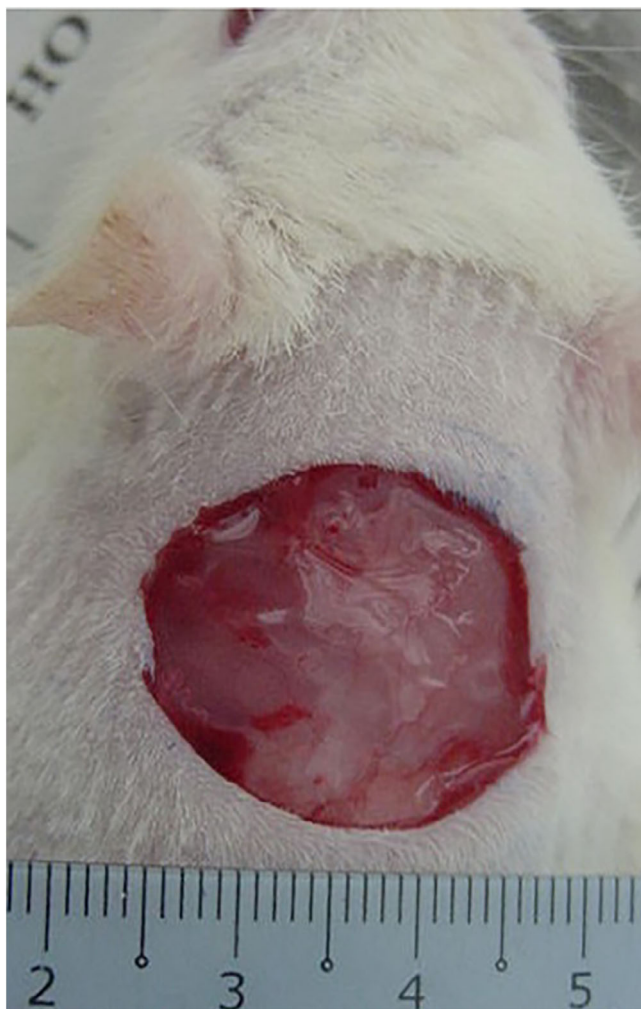## 2.4.2 | Immunohistochemistry

Skin tissues transferred into 10% formilon solution, after which undergo a process of fixation, dehydration, clearing, deparaffinization (xylene), blocking, and slicing at 4 μm tissue thickness using microtome (Top, Zhejiang, China). The antigens were boiled in a microwave and then, recovered using sodium citrate buffer. The immunohistochemicals in recovered skins were estimated based on the streptavidin-biotin procedure.<sup>32</sup> Briefly, endogenous peroxidase enzymes blocked with methanol and with 0.03% hydrogen peroxide (plus sodium azide) for

10 min. The skin tissues were buffer washed and then, they were incubated with either HSP 70 (1:500) or Bax (1:200) antibodies for fifteen minutes following company's guidelines (Sigma Aldrich, Germany). After buffer washing of tissue sections, They were incubated with the biotinylated second antibody and streptavidin-peroxidase (contained anti-microbial agents) for 45 min. The sections were buffer washed again, incubated with Diaminobenzidine substrate-chromogen for five minutes, and then, they were counter stained with Mayer's hematoxylin. After immersing in an ammonia solution (37 mmol) in ten times, the tissue sections were water washed and fixed on slides for a light microscope examination (BIM-3200, China). A brown color appearance considered as a positive stain for the estimated immunohistochemicals.

## 2.4.3 | Enzyme activity

On final day of the experiment (day 15th), the obtained homogenized tissue samples prepared with 1.15% calcium chloride (1:5 w/v) using a Teflon homogenizer (Polytron, Germany). The mixture was centrifuged at 5000 rpm for 5 min and the supernatant was separated



**FIGURE 2** Dorsal neck cut created by a round seal on day 0.

for evaluation of different enzymatic contents. The concentrations of catalase, malondialdehyde, and superoxide dismutase enzymes were determined in tissue homogenates activity in tissue homogenate, using ELISA commercial kits (Biotech Co., Ltd, Wuhan).<sup>33,34</sup>

#### 2.4.4 | Hydroxyproline

The skin tissues from healed area were obtained and transferred into homogenizer (Teflon homogenizer, Polytron, Germany). After centrifugation of the tissue mixture at 4500 rpm for 15 min at 4°C, the separated supernatant was analyzed for the hydroxyproline (HXP) content following producer's manual instruction (Sigma Aldrich, China)<sup>35</sup>.

#### 2.4.5 | Inflammatory mediators

The obtained intracardiac blood samples centrifuged and analyzed for inflammatory mediators using ELISA kits (Elabscience, Wuhan, China) following company's instructions.<sup>36</sup> The cytokine strength was detected using normal sanitized recombinant cytokines. The serum

samples of 100  $\mu$ L were transferred into an incubator for overnight (at 4°C) after placing them in 96-well plates. The plates incubated with % skimmed milk for 1 h at 37°C to create non-specific binding site. After washing (0.05 M Tris-HCl buffer tween 20) the probes, antibodies added to samples and they were incubated for 60 min at 37°C. Next, the second incubation of samples included appropriate secondary antibodies. Between all these steps, samples were washed with 0.05 M Tris-HCl buffer (0.1% Tween-20) two times. The substrate o-phenylenediamine/hydrogen peroxide was used for the peroxidase reaction (Sigma-Aldrich, China) and the spectral measurement performed at 492 nm.

### 2.5 | Statistical analysis

The present data was prepared as mean  $\pm$  SEM with  $p < 0.05$  as significance level. The data was analyzed by ANOVA, SPSS software, and the designing figures were possible by using Graph Pad Prism 9.0.

## 3 | RESULTS

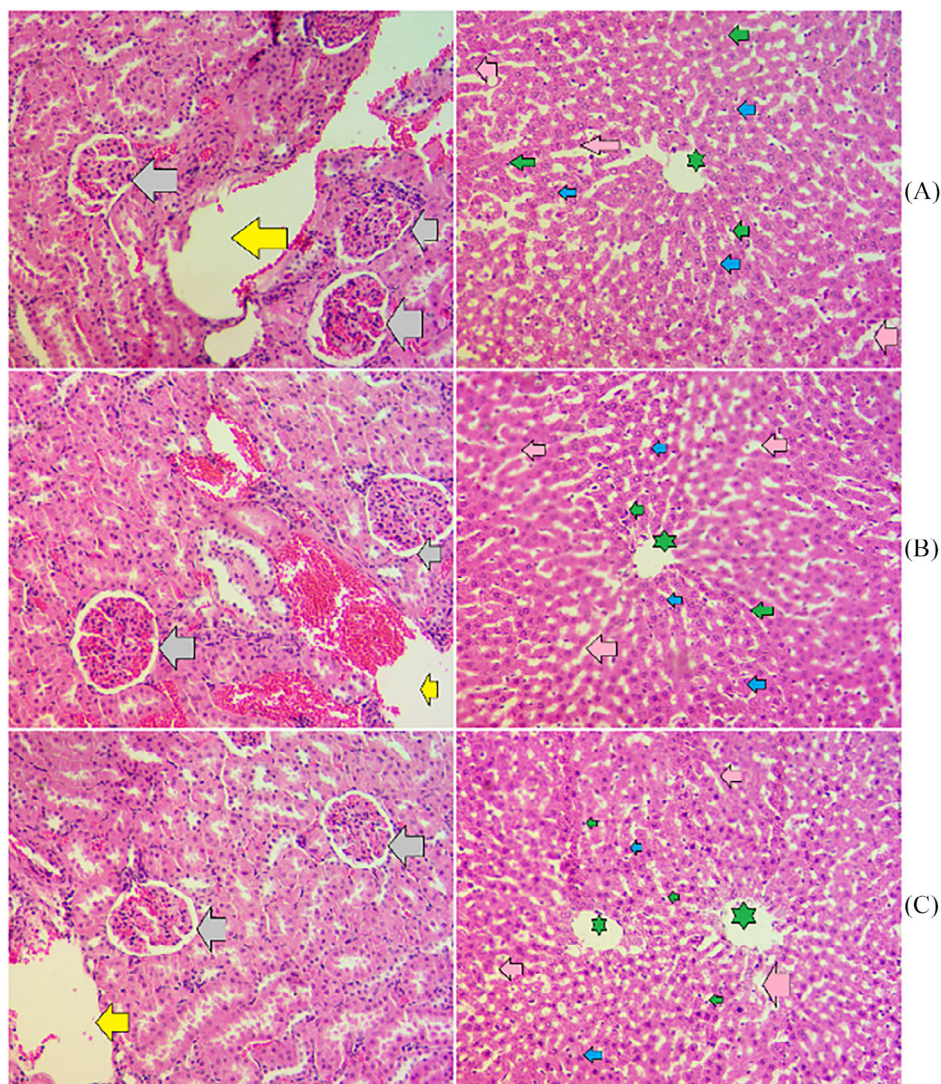
### 3.1 | Acute toxicity

The current acute toxicity trial revealed lack of any toxicity effects of oral delivery (2 and 5 g/kg) to rats in a 14 days' trial. DAG-treated rats seemed very active and functioning normally throughout the experimental period and they had the same amount of feed intake and bodyweight compared as the normal controls. Furthermore, even after the 14 days of experiment, DAG-treated rats did not develop any physical abnormalities (wound area bite, irritation, restlessness, convulsion, and pain). The histopathological evaluation of kidney and livers obtained from treated rats revealed comparable tissue structure to that of normal controls (Figure 3). The outcomes expect that the toxic dosage of DAG would be higher than 300 mg/kg. Moreover, serum biochemical analysis found nonsignificant difference in the of liver and kidney profiles of normal control and DAG-treated rats (data can be shown on request).

### 3.2 | Wound experiment

#### 3.2.1 | Wound size and closure percentage

The present wound estimation showed different wound areas in different wounded rats addressed topically with 0.2 mL of normal saline, intrasite gel, and 250 and 500 mg/kg of DAG on days 5, 10, and 15 after excision. The vehicle rats, as expected, had significantly higher wound areas compared to all other treated rats based on histopathological and epidermal estimation on days 5, 10, and 15 after injury. While the intrasite gel or DAG (0.2 mL of 250 and 500 mg/kg)-treated rats showed a gradual reduction in their wound area as time passed, which was significantly different from that of vehicle rats. The closure percentages of wounds after 15 days of excisional procedure were significantly



**FIGURE 3** Histology effects of oral ingestion in rats in toxicity experiment. (A) Normal control rats ingested normal saline; (B) received low dose (2 g/kg) of DAG; (C) high dose (5 g/kg) of DAG. There were non-significant changes in the tissue structure of liver and kidneys obtained from normal and DAG-treated rats. Grey arrow, normal glomeruli; yellow arrow, blood vessel; green star, central vein; pink arrow, sinusoidal capillary; hepatocyte with round nucleus, blue arrow; Kupffer cell, green arrow.

lower (64.97%) compared to that (92.58% and 87.80%) of intrasite gel and DAG (0.2 mL of 250 mg/kg)-treated rats, respectively. Contrary, rats addressed with 0.2 mL of 500 mg/kg DAG-treated rats had significantly higher (90.85%) wound closure percentages than the vehicle normal saline rats. Moreover, during all three periods of wound estimations, the wound area and closure percentages were very similar and non-significantly different between intrasite gel and DAG (0.2 mL of 500 mg/kg)-treated rats as shown in Table 1 and Figure 4.

The topical application of DAG caused a significant acceleration of wound-curing action that were significantly different than in the vehicle rats based on the morphological evaluations on day 5, 10, and 15 after injury (Figure 4). Topical treatment of rats with intrasite gel or DAG for 5 and 10 days after the excisional procedure caused similar wound closure, but they were significantly different from that of vehicle rats (Figures 4). After 15 days of topical applications, the wound area and closure percentages significantly differed between experi-

mental rats, which were significantly higher in intrasite gel or DAG (0.2 mL of 250 mg/kg)-treated rats (Figure 4). The outcomes indicate significant wound healing potentials of DAG, more significantly after 15 days of application on excisional wounds.

### 3.2.2 | Histopathological effect of DAG

The results have significant differences in the granulation tissues between normal saline-treated rats compared to intrasite gel or DAG-treated rats based on different histopathological examinations by using H & E and Masson Trichrome stains. The vehicle rats had numerous invasive inflammatory cell infiltration, dermal vacuolization, adipose tissue immaturity, and clear indications of edema, hemorrhage, and lack of hair follicles and sweat glands in dermal layers. Conversely, rat groups received 0.2 mL of 250 and 500 mg/kg DAG showed higher

**TABLE 1** Wound estimation in rats received with at different treatments.

Clusters	Wound area (mm <sup>2</sup> )		Day 5 Closure (%)	Wound area (mm <sup>2</sup> )		Day 10 Closure (%)	Wound area (mm <sup>2</sup> )	
	Day 0	Day 5		Day 10	Day 15		Day 15 Closure (%)	
A	235 ± 0.48	171.7 ± 3.2 <sup>c</sup>	26.93	100.3 ± 4.7 <sup>c</sup>	57.31 <sup>b</sup>	82.3 ± 2.8 <sup>c</sup>	64.97 <sup>c</sup>	
B	235 ± 0.46	97.22 ± 3.63 <sup>a</sup>	58.62	42.38 ± 2.8 <sup>a</sup>	81.96 <sup>a</sup>	17.43 ± 2.5 <sup>a</sup>	92.58 <sup>a</sup>	
C	235 ± 0.49	88.4 ± 4.11 <sup>b</sup>	62.38	58.45 ± 3.8 <sup>b</sup>	75.12 <sup>a</sup>	28.66 ± 2.7 <sup>b</sup>	87.80 <sup>b</sup>	
D	235 ± 0.50	91.22 ± 3.43 <sup>b</sup>	61.18	51.23 ± 4.5 <sup>b</sup>	78.2 <sup>a</sup>	21.50 ± 2.3 <sup>a</sup>	90.85 <sup>a</sup>	

Rat clusters received 0.2 mL of topical treatments: Group A, rats received normal saline; B, rats had intrasite gel; C and D, rats had 250 and 500 mg/kg of DAG. Similar letters on values within column indicate non-significant at  $p < 0.05$ .

recovered skin tissues compared to vehicle rats shown by increased tissue granulations, tissue re-epithelialization, mild inflammatory cells, more fibroblasts, and neovascularization with myofibroblast irregularities (Figures 5 and 6).

The wound tissues staining by Masson's trichrome stain showed different growth rates in the dermal skin layers and various collagen deposition in experiment rats. The vehicle rats showed reduced expression of MT stain and increased dermal immaturities near the wound area represented by reduced granulated tissues and up-regulation of the inflammatory cells distributed near the wound area. While the intrasite gel or DAG-treated rats showed an elevated production rate of collagen deposition in a more ordered format compared to that of vehicle rats, the outcomes denote significant wound healing potentials of GAD mediated by the upregulation of tissue granulation and tissue proteins and downregulation of inflammatory cell infiltrations (Figures 7 and 8).

### 3.2.3 | Effect of DAG on the expression of HSP 70 protein in injured skin tissues

The results showed various HSP 70 protein expressions in injured skin tissues based on immunohistochemistry technique. The vehicle rats showed significantly the lowest level of HSP 70 expressions (very reduced light brown color) in their granulation tissues; however, the inflammatory cells were increased distributed all over the tissues. Conversely, DAG-treated rats had significantly intense expression of HSP 70 proteins (deep brown color), which were significantly higher compared to vehicle rats. The stimulatory action of DAG on the HSP 70 proteins in injured skin tissues was very comparable to that of intrasite gel-treated rats. The outcomes suggest significant inducible potentials of DAG that subsequently accelerate the wound curing process (Figure 9).

### 3.2.4 | Effect of DAG on Bax protein expression in injured skin tissues

The present immunohistochemical evaluation of Bax protein expression in wound tissues revealed significant difference in treated rats exposed to various topical treated after 15 days of excisional process. The vehicle rats experienced increased Bax proteins expressions

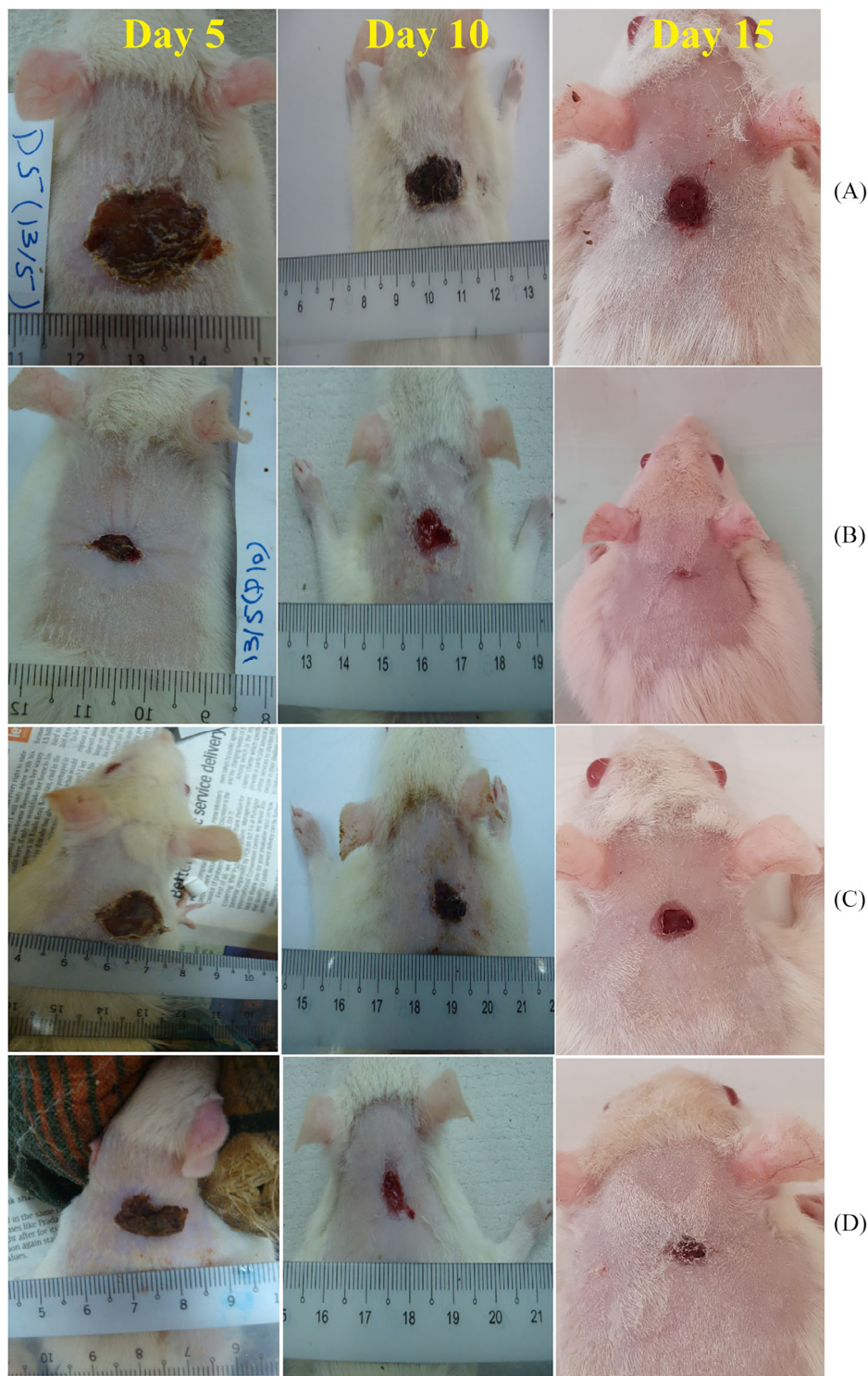
in their granulated tissues, indicating that the tissues are still in the inflammatory stage of the wound healing process. Topical addressing by intrasite gel or DAG caused significantly decreased expression of Bax proteins in their wound tissues, denoting that the skin is passed the inflammatory phase and entered the later phases of healing process. The reduced Bax protein appearance in intrasite gel or DAG-treated rats is possible to eliminate the scares and as normal maintenance function of skin tissues (Figure 10).

### 3.2.5 | Effect of DAG on oxidative stress

As shown in Table 2, rats received topically with different treatments showed various levels of endogenous antioxidants and MDA levels in their wound tissues. The normal saline treated rats experienced significant oxidative stress shown by reduced antioxidant enzymes and elevated MDA values in the injured skin tissue homogenates. The intrasite gel or DAG-treated rats showed better antioxidant status in their wound tissues represented by higher SOD, CAT, and lower MDA contents compared to vehicle rats. DAG application (0.2 mL of 500 mg/kg) on dorsal neck injury caused positive augmentation of endogenous antioxidants shown by higher SOD (7.92 U/mg) and CAT (44.83 umol/min/mg) and lower MDA (4.10 nmol/mg) levels compared to that (5.67 U/mg, 27.6 umol/min/mg, and 10.27 nmol/mg, respectively) of vehicle rats. These increased antioxidant enzymes in DAG-treated rats indicate lower oxidative tissue injury, subsequently leading to faster wound-healing actions. Moreover, the lipid peroxidation indicator (MDA) was significantly higher, which consequently caused more oxidative stress and a delay in the wound curing process. The intrasite gel or DAG-treated rats had reduced lipid peroxidation rate shown by decreased MDA values compared to that of normal saline (vehicle) rats. The suggested antioxidant potentials of DAG can be proposed as cellular process aided in faster wound healing action and higher percentage of wound contraction in DAG-treated rats.

### 3.2.6 | Effect of DAG on hydroxyproline

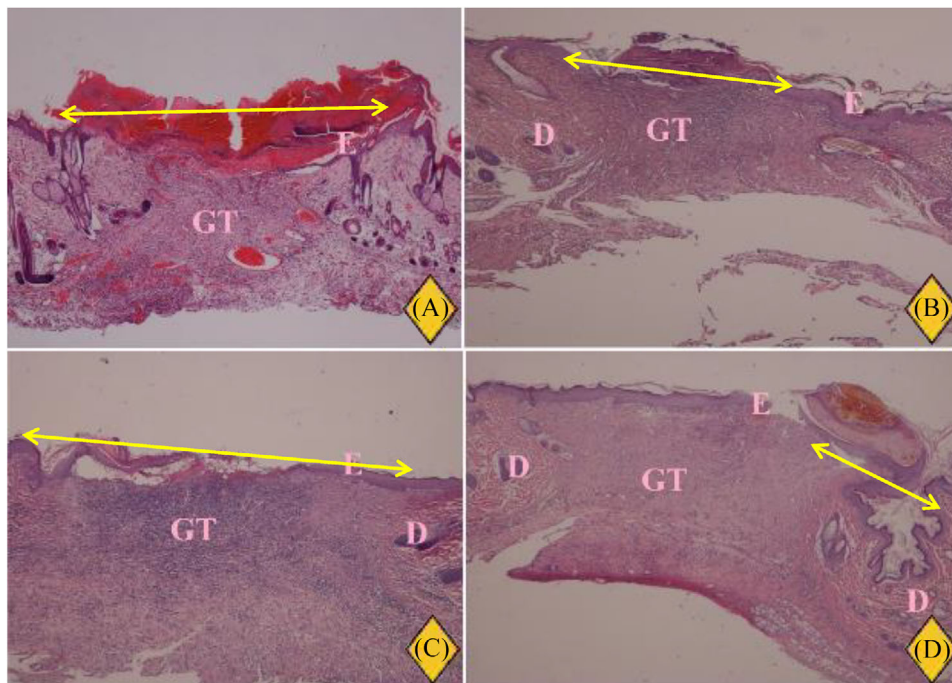
The hydroxyproline (major collagen constituent) content of skin tissues was significantly modulated by topical treatments applied on dorsal neck injury as shown in Figure 11. The normal saline treated



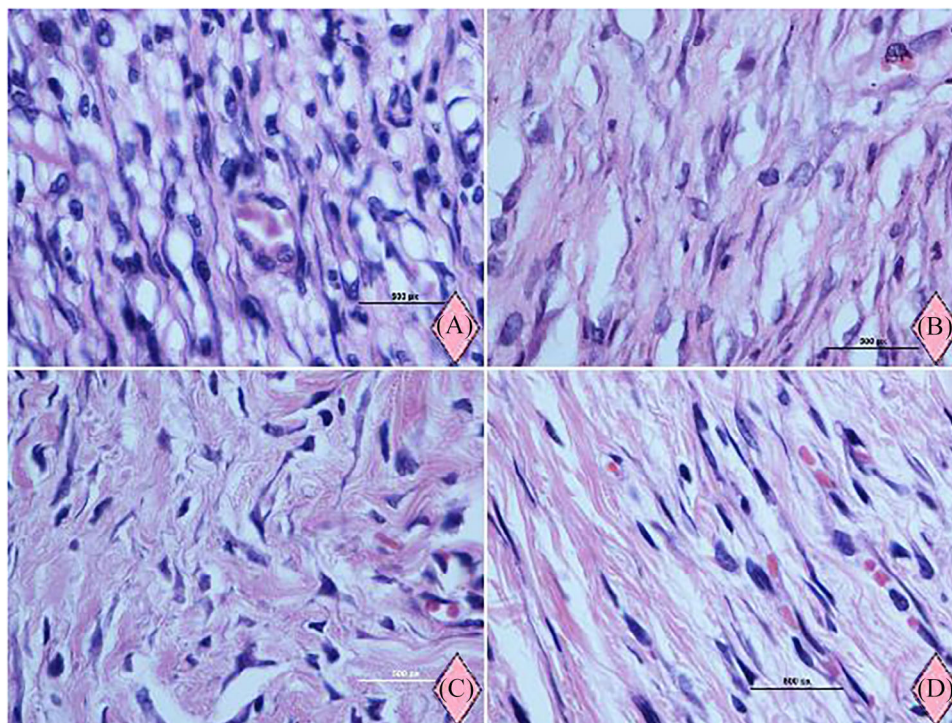
**FIGURE 4** The dorsal skin cuts from different treated rats on three time intervals. Group A, rats addressed 0.2 mL of normal saline; (B) Rats received topical treatment of reference intrasite gel; (C and D) Rats treated with 0.2 mL of 250 and 500 mg/kg of DAG. DAG treatment (0.2 mL of 500 mg/kg) led to significant acceleration of wound contraction, which resembled those found in intrasite gel-treated rats.

rats showed decreased levels (41.24 mg/kg) of hydroxyproline in their skin tissues, denoting reduced collagen content in their granulation tissues and an early inflammatory phase of the wound curing process. Rats that received topically 0.2 mL of intrasite gel showed noticeably higher (92.50 mg/g) amount of hydroxyproline in their

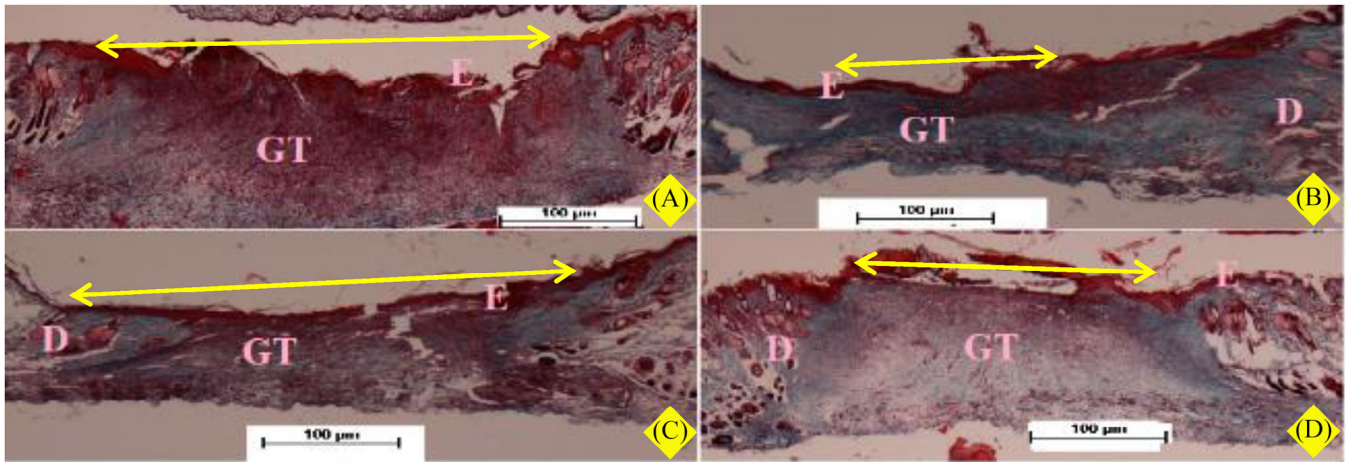
wound tissues, which was expected due to its stimulatory action on cellular proliferation and collagen formation. DAG treatment (0.2 mL of 250 and 500 mg/kg) caused noticeable higher (56.30 and 73.52 mg/kg, respectively) hydroxyproline production compared to normal saline-treated rats, indicating that the wound tissues are in



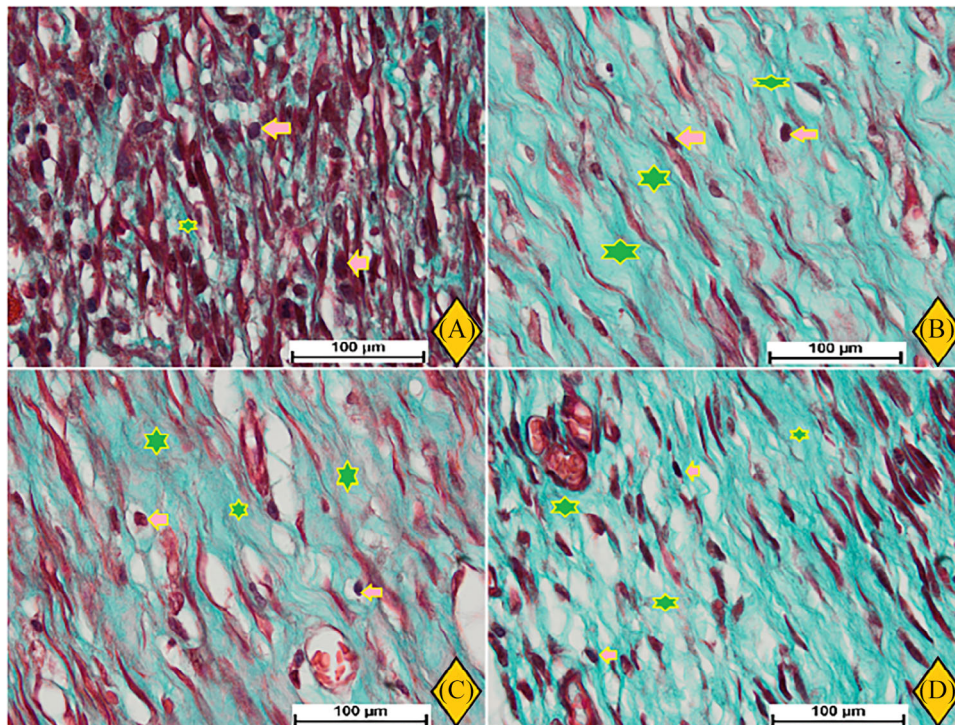
**FIGURE 5** Microscopic observation (low magnification) of skin cuts on day 15. Group A, rats addressed 0.2 mL of normal saline; (B) Rats received topical treatment of reference intrasite gel; (C and D) Rats treated with 0.2 mL of 250 and 500 mg/kg of DAG. DAG-treated rats had comparable wound closure area compared to intrasite gel-treated rats. Yellow arrows indicate wound closure area; D, dermis; GT, granulation tissue; E, epidermis (H&E stains, 2x).



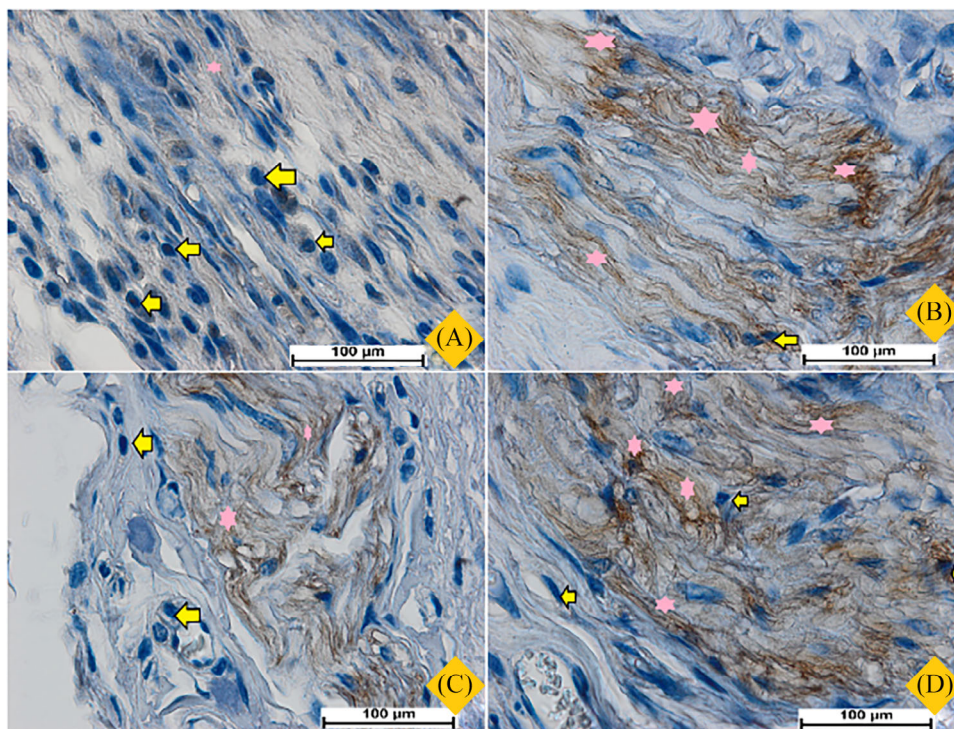
**FIGURE 6** Microscopic observation (high magnification) of skin cuts on day 15. Group A, rats addressed 0.2 mL of normal saline indicated with large skin damage, reduced collagen, and fewer fibroblasts; (B) Rats received topical treatment of reference intrasite gel, which had fastest skin recovery attributed with magnified collagen deposition (deep green color); (C and D) Rats treated with 0.2 mL of 250 and 500 mg/kg of DAG. DAG-treated rats had comparable wound closure and collagen content compared to intrasite gel-treated rats. Yellow arrows indicate wound closure area; GT, granulation tissue; E, epidermis; D, dermis (H&E stains, 100x).



**FIGURE 7** Microscopic observation of recovered dorsal neck skin (stained with Masson's Trichrome) obtained from rats on day 15. Group A, rats addressed 0.2 mL of normal saline indicated with large skin damage, immature dermis, and minimum collagens (bright green coloration) in their granulation tissue (GT); (B) Rats received topical treatment of reference intrasite gel, which had fastest skin recovery attributed with magnified collagen deposition (deep green color); (C and D) Rats treated with 0.2 mL of 250 and 500 mg/kg of DAG had moderate to elevated collagen content, which were very comparable to intrasite gel-treated rats (Masson's Trichrome, 2x). GT, granulation tissue, D, dermis; E, epidermis (Magnification 2x).



**FIGURE 8** Microscopic observation of recovered dorsal neck skin (stained with Masson's Trichrome) obtained from rats on day 15. Group A, rats addressed 0.2 mL of normal saline indicated with large skin damage, immature dermis, increased inflammatory cells (orange arrow), and minimum collagens (asterisk) in their granulation tissue (GT); (B) Rats received topical treatment of reference intrasite gel, which had fastest skin recovery attributed with magnified collagen deposition (deep green color); (C and D) Rats treated with 0.2 mL of 250 and 500 mg/kg of DAG had moderate to elevated collagen content, which were very comparable to intrasite gel-treated rats (Masson's Trichrome, 2x). GT, granulation tissue, D, dermis; E, epidermis (Magnification 100x).



**FIGURE 9** Microscopic observation of skin cuts obtained from all rats expressing different HSP 70 concentrations. Group A, normal control rats received 0.2 mL of normal saline showed noticeably decreased HSP 70 protein (pink star) indicated by thin brown color) and magnified inflammatory cells (yellow arrow); Group B, intracite gel-treated rats revealed noticeably reduced HSP 70 intensity denoted by deep brown color; Groups C and D rats had topical addressing of 0.2 mL of 250 mg/kg of DAG experienced moderate to increased expression of HSP 70 proteins (brown color) and reduced inflammatory indicator compared to normal saline-treated rats (Magnification 100x).

later stages (tissue regeneration and remodeling) of wound healing action. The outcomes suggest significant modulatory potentials of DAG on skin collagen, which subsequently accelerated the wound healing process.

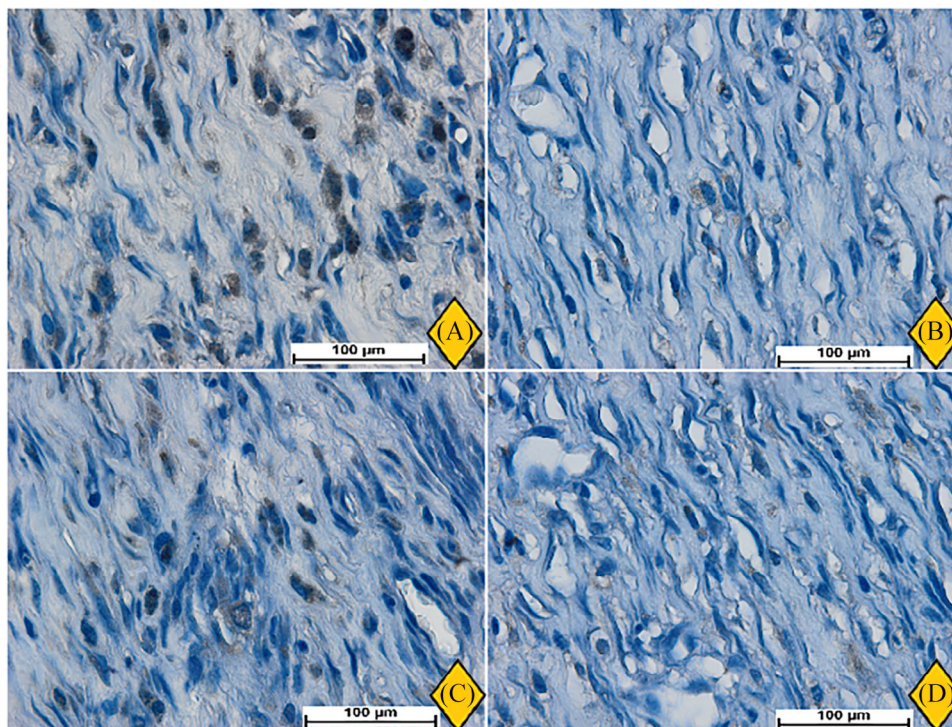
### 3.2.7 | Effect of DAG on inflammatory cytokines

The serum inflammatory profiles were significantly modulated by different topical treatments on dorsal neck injury in rats. The pro-inflammatory cytokines were significantly upregulated (TNF- $\alpha$ ; 136.30 pg/mL and IL-6; 61.20 pg/mL) and the anti-inflammatory cytokines were downregulated (IL-10; 263.31 pg/mL) in normal saline (vehicle)-treated rats. Intracite gel or DAG-treated rats had reversed estimations of inflammatory cytokines compared to vehicle rats. The present results showed increased immunomodulatory action of DAG (0.2 mL of 500 mg/kg) represented by decreasing TNF- $\alpha$  (62.12 P.pg/mL) and IL-6 (21.82 pg/mL) and increased IL-10 levels (646.29 pg/mL), which were noticeably varied compared to normal saline addressed rats. Moreover, DAG (0.2 mL of 500 mg/kg)-treated rats revealed comparable TNF- $\alpha$  and IL-10 levels and non-significant differences in the IL-6 values compared to intracite gel-treated rats (Figure 12). The present data showed significant anti-inflammatory potential of DAG, which might be linked with its stimulatory potentials in wound recovery.

## 4 | DISCUSSION

The investigation of the toxicity effect of plant extracts is an indispensable safety measurement; it defines the intrinsic toxicity of the herbs and the toxic damage of overdose. Therefore, to avoid negative outcomes, an acute toxicity test has been followed by scientists as a safety check of any natural products that are of medicinal interest.<sup>37,38</sup> The present work evaluated the lethality of DAG (250 and 500 mg/kg) that traditionally utilized for wound healing and management of skin cracks.<sup>39</sup> The toxicity trial revealed non-toxic effects of DAG in rats without any observable behavioral or physiological changes during or after the 14-day trial. Moreover, the serum biochemical profile and histological evaluations of the livers and kidneys showed comparable results for normal and DAG -treated rats. Similarly, researchers reported lack of toxicity and significant positive modulation of sperm counts in nicotinamide-streptozotocin-mediated diabetes in rats exposed to oral ingestion of hydro-alcoholic extract of *D. aucheri* (100, 200, 400 mg/kg).<sup>40,41</sup> Accordingly, hydro-alcoholic extracts (100, 200, 400 mg/kg) of *D. aucheri* showed non-toxic and alleviated symptoms in diabetic in rats.<sup>41</sup>

Wound recovery is a natural physiological action that occurs in damaged skin tissues and aids in regaining the structure, function, and integrity of damaged skin tissues. The wound healing action includes several integrated and sequential stages to recover cells and tissues



**FIGURE 10** Microscopically views of skin tissue presenting different levels of Bax proteins on day 15 after excisional process; Group A, rats addressed with 0.2 mL of normal saline showed increased Bax proteins expression (numerous brown spots); Group B, rats had 0.2 mL of intrasite gel represented significantly very reduced Bax proteins (few or lack of brown spots); Group C, rats addressed with 0.2 mL of 250 mg/kg of DAG showed reduced Bax proteins expression but not as significant as group B; Group D, rats had topical addressing of 0.2 mL of 500 mg/kg DAG present very low expression of Bax proteins shown by few brown spots in their granulation tissues (Magnification 100x).

**TABLE 2** Effect of DAG on SOD, CAT, and MDA level in homogenized healed skin.

Animal groups	SOD (U/mg protein)	CAT (umol/min/mg)	MDA (nm/mg protein)
A	5.67 ± 1.8 <sup>c</sup>	27.6 ± 3.2 <sup>c</sup>	10.27 ± 1.8 <sup>c</sup>
B	12.24 ± 2.3 <sup>a</sup>	50.28 ± 3.3 <sup>a</sup>	3.23 ± 0.7 <sup>a</sup>
C	6.78 ± 2.4 <sup>b</sup>	40.22 ± 2.6 <sup>b</sup>	5.38 ± 0.8 <sup>b</sup>
D	7.92 ± 2.8 <sup>b</sup>	44.83 ± 3.7 <sup>b</sup>	4.10 ± 0.4 <sup>a</sup>

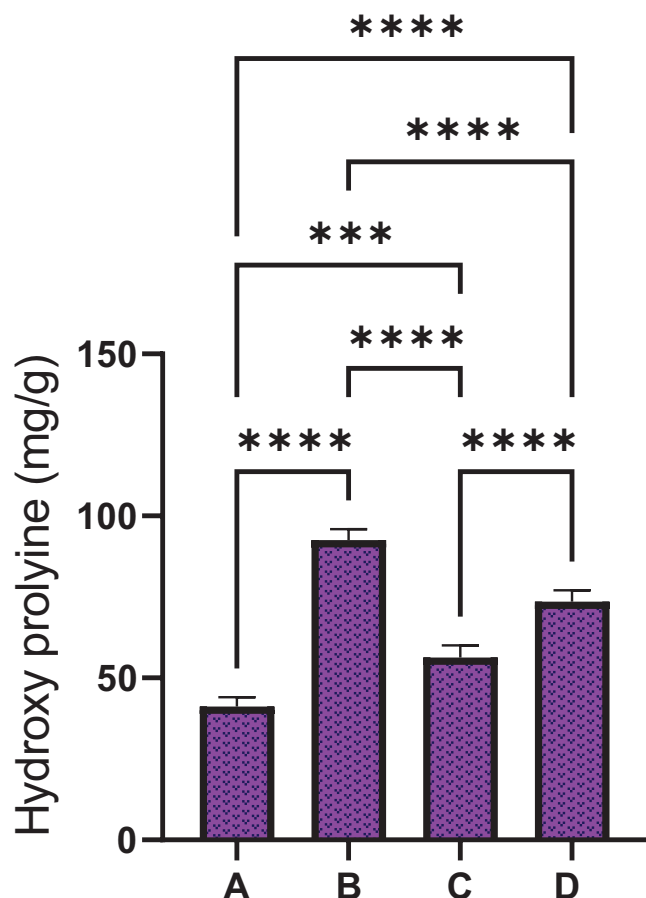
Rat clusters received 0.2 mL of topical treatments: Group A, rats received normal saline; B, rats had intrasite gel; C and D, rats had 250 and 500 mg/kg of DAG.

Vallues with different letters within column presents significance at  $p < 0.05$ .

to have the same pre-wound status. The process of wound curing could be halted by several factors.<sup>42</sup> Pathogen penetration (microbes) is one crucial risk factor that causes local and systematic infections, and the severity changes based on the degree of tissue injury and the cause of infection. Infected wounds require a much longer period to recover than non-infected wounds because of increased microbial growth and the prolonged inflammation phase of wound healing.<sup>43</sup> The present results showed increased wound-curing potentials of DAG on dorsal neck injuries in rats. Vehicle rats normal saline showed increased wound area and reduced wound closure percentages during all three periods of wound estimations compared to intrasite gel

or DAG-treated rats. The normal saline treated rats had thick and stiff wounds with brown scabs, larger wound areas, reduced epithelialization, and lower wound closure compared to DAG-treated rats. Histopathological study of healed skin tissues by using H&E and Masson's trichrome stains showed less scar width at wound closure in DAG-treated rats than in the normal saline treated rats. Moreover, the tissue collagens and neovascularization (blood capillaries) were significantly upregulated and the inflammatory cells (leukocyte infiltration) were significantly lower in DAG-treated rats. DAG treatment caused the production of a protective cover over the wound area that thickened the skin epidermis and prevented microbial penetrations, subsequently less tissue damage and faster wound healing actions occurred in those groups. The wound-healing potentials of DAG could be related to its increased flavonoid and phenolic chemical contents, which were repeatedly reported as wound-curing agents in different in vivo trials.<sup>44,45</sup> Accordingly, numerous researchers revealed wound healing potentials of Dorema gum due to its chemical potential in the augmentation of the inflammatory cells and angiogenesis in different animal models.<sup>46,47</sup>

Programmed cell death (apoptosis) as an energy-reliable cellular process plays a crucial part in the progression and pathogenesis of wound recovery. Neutrophils are the first inflammatory cells that travel toward the wound area and stimulate the inflammatory cascade. The main function of neutrophils is to eliminate pathogens and microbes. This commonly occurs through phagolysosomes, but often causes



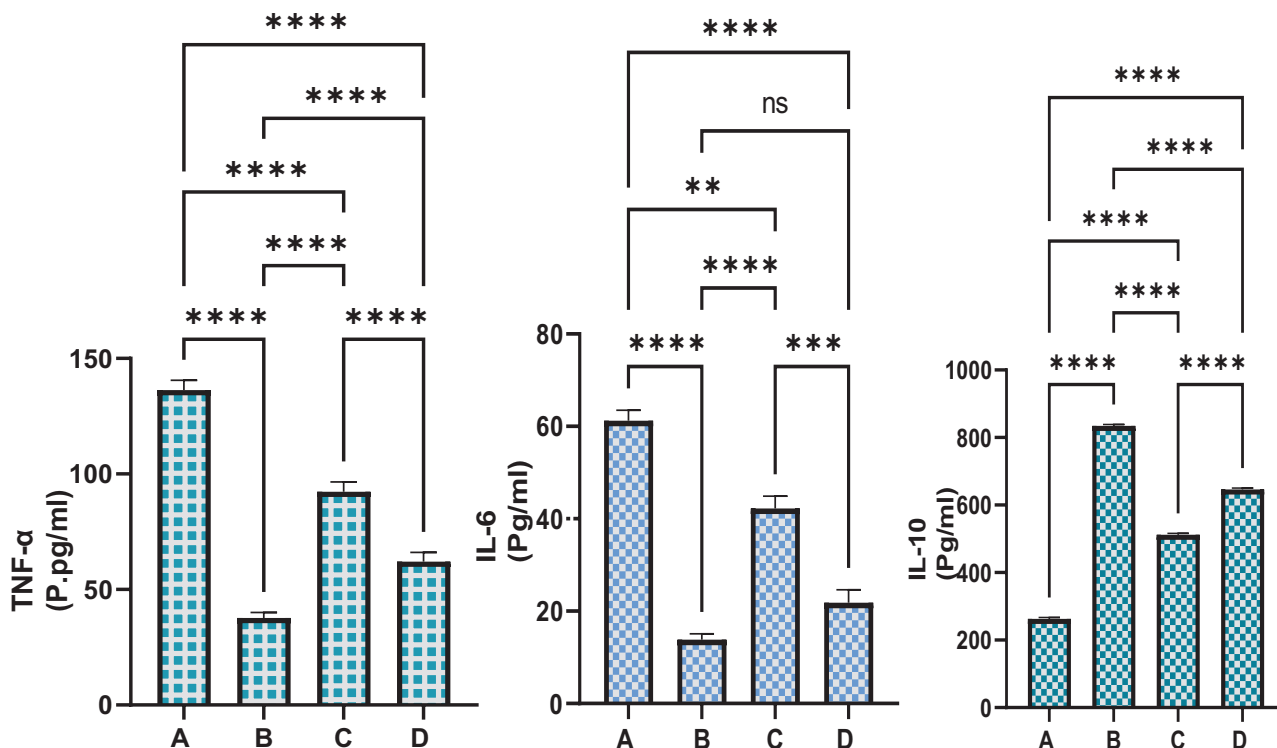
**FIGURE 11** The hydroxyproline content in recovered wound tissues obtained from different rat clusters. Rat clusters received 0.2 mL of topical treatments: Group A, rats received normal saline; B, rats had intrasite gel; C and D, rats had 250 and 500 mg/kg of DAG. The HXP content was significantly upregulated following DAG treatment, indicating increased collagen production and accelerated wound contraction.

increased production of free radicals in host cells, subsequently killing other healthy cells along with the target infectious substance. This usually occurs in chronic wounds and could be the deleterious-tissue-damaging nature of such wounds. Scientists revealed that another mechanism for microbial elimination by neutrophils involves surrounding microbes with a net of histones and DNA.<sup>48</sup> Macrophages, which reach the inflammatory area a little later, perform phagocytic action that clears wound areas from all the cell debris and cellular matrix (fibrin clotting factor). Macrophages secrete numerous inflammatory cytokines, growth factors, and angiogenic factors that aid in the modulation of angiogenesis and fibro-proliferations. Another inflammatory cell that is considered a valuable leukocyte lineage, the mast cell, originates from basophils that mediates the later inflammatory stages aiding in faster wound contraction.<sup>49</sup> Increased production of reactive oxygen species causes activation of apoptotic proteins (Bax) that initiate apoptosis in the surrounding cells, keratinocytes.

Research studies have validated a direct correlation between the intensity of Bax protein and the apoptotic actions during the wound-

curing process. The skin tissue staining by immunohistochemical (Bax) proteins in rats received normal saline, which revealed that the wound-curing process is still at an early stage of the inflammatory phase.<sup>10,29</sup> However, rats treated with intrasite gel or DAG had noticeably reduced Bax protein intensity in their wound tissues demonstrating that the wound curing process was at a later phase of recovery. The reduced Bax protein expression possibly aids in clearing wound areas and as a part of the normal balancing of skin tissues. Moreover, heat-shock proteins (HSPs) are a well-documented family of conserved proteins that are considered copious proteins that enhance wound-curing action by increasing macrophage-mediated phagocytosis.<sup>50</sup> Scientists have shown that the intensity of HSP proteins increased in cells as a result of various stress-related factors, including skin injury. These immunoreactive protein molecules contribute majorly to the activation of macrophages, alarming host cells to initiate to immune response. HSP proteins conjugate with several receptors on the surface of macrophage and increase various cellular processes, including inflammatory cytokine production, phagocytic actions, tumor rejection, and elevation of co-stimulatory actions.<sup>51</sup> Moreover, HSP can have regulatory action on protein synthesis and conformation, protein recovery, and enhanced tissue healing actions. It has been validated that HSP70 is the most prevalent HSP in wound tissues; therefore, its intensity was estimated in the current study. The normal saline treated rats showed decreased expression of HSP70 proteins; however, the inflammatory cells (mononuclear cells) were more abundant around wound areas. The brown staining on skin tissues as an indication of the Hsp70 protein was significantly higher in intrasite gel or DAG -treated rats. This modulatory action on the immunohistochemical proteins by DAG could be correlated with its phytochemical contents (flavonoid and phenolic). Accordingly, numerous flavonoid-rich plant extracts have shown significant regulatory potentials on the apoptotic (Bax) and HSP 70 proteins.<sup>52,53</sup>

The curing process of damaged skin tissue may take more time to recover completely due to skin ischemia, a skin disorder characterized by low blood supply, enhancing the production of ROS by upregulation of the leukocyte proliferation around wound areas. As the process continues; more free radicals near the injury site can provoke the inflammatory actions and mediate the release of more cytokines and leukocyte infiltrations.<sup>7</sup> As a defence mechanism, antioxidant enzymes are released by surrounding cells and injured cells to limit free radicals damage. In cases of deep skin injury, where tissues are overwhelmed with ROS, a serious biological destructive cascade becomes activated that consequently changes cellular structure and function leading to cell death. The present data showed reduced antioxidant enzymes in normal saline-treated rats.<sup>30</sup> DAG treated upregulated the free radical quenching enzymes estimated in skin tissue homogenates, which might be one of the mechanisms behind faster wound recovery in these groups. Accordingly, numerous scientists reported the antioxidant potentials of *D. aucheri* in different in vitro and in vivo trials, expecting a causal link related to the *D. aucheri* content of phenolic acid and flavonoids.<sup>20,24,41,54</sup> Similarly, the researcher showed significant antioxidant potentials of ammoniac gum in different assays (DPPH, ABTS, and FRAP), which were mainly correlated with its



**FIGURE 12** Effect of DAG topical treatment on the serum inflammatory profile in rats. Rat clusters received 0.2 mL of topical treatments: Group A, rats received normal saline; B, rats had intrasite gel; C and D, rats had 250 and 500 mg/kg of DAG. DAG treatment led negative modulation of the inflammatory mediators and positive regulation of anti-inflammatory chemicals consequently facilitated faster wound-contraction.

phytochemical contents (polysaccharides including galactose glucuronic acid, arabinose, and rhamnose).<sup>55</sup>

Lipid peroxidation, as a cellular process, occurs as a result of polyunsaturated fatty acids oxidation, and subsequently increases the ROS pool, including hydroxyl radicals near the wound bed. Free radical accumulation in wound tissues induces cellular damage and dysfunctionality of collagen and fibroblast impairment. Moreover, the endothelial cell functionality, keratinocyte permeability, altered rigidity, and ion leakage (calcium) are heavily affected by the lipid peroxidation byproduct.<sup>10</sup> The vascular-endothelial growth factors are also reduced as a result of increased lipid peroxidation, thereby slowing the wound-healing process. One of the most copious carbonyl substances of lipid peroxidation, MDA, is evaluated in skin tissue homogenates.<sup>29</sup> The topical application of normal saline on dorsal neck injury caused significant upregulation of MDA in skin tissues, denoting increased lipid peroxidation that could be one of the causes behind the slower wound healing process. Rats who received DAG treatment had lower MDA levels in their wound tissue homogenates, indicating elevated antioxidant potentials in quenching free radicals that facilitated faster wound recovery. Accordingly, previous studies have shown the inhibitory potentials of *D. aucheri* on the MDA levels, which were correlated with its chemical profiles.<sup>41,54</sup>

Fibroblasts are important cell types found in the connective tissue and are linked with the biosynthesis of collagen, elastin, and glycosaminoglycan. The abundance of fibroblasts and fibrocytes

number/mm<sup>2</sup> near the wound bed is directly proportional to the amount of synthesized and deposited collagen fibers.<sup>56</sup> The physiological function (e.g., secretion of ECM and secretion and signaling factors for mechanical force generation and tissue remodeling and tissue metabolism) of fibroblasts is significantly reduced by the accumulation of ROS in skin tissues. Thus, antioxidants such as phenolic and flavonoids can have stimulatory effects on the wound-healing process by reducing free radicals and increasing fibroblast and collagen fibers in wound tissues.<sup>7</sup>

Hydroxyproline is a major constituent (13.5% of its amino acid) of skin collagen maintaining collagen structure (twisting helix) including its integrity and structural stability.<sup>57</sup> Collagen fiber is considered an important contributor to wound recovery due to its contribution in the final phases of wound contraction. In the current study, DAG-treated rats had increased HXP levels in their skin tissues than in the normal saline-treated rats, indicating its positive modulation of collagen deposition which accelerated wound contraction. Similarly, scientists showed significant upregulation of skin collagens by the ammoniac gum, which was applied on two full-thickness dorsal wounds in rats, which was linked with its polysaccharide contents.<sup>47</sup>

The systemic pro-inflammatory cytokines (TNF- $\alpha$  and IL-6) were noticeably increased during the early days after the excisional procedure and wound creation on the dorsal neck. TNF- $\alpha$  is a valuable facilitator of wound contraction by enhancing re-epithelialization, fibroblast proliferation, and new blood capillary formation. The

pro-inflammatory cytokines are essential for immune cells (neutrophils) attraction to inflammatory site and eliminating pathogens that may grow near the wound bed.<sup>58</sup> Furthermore, pro-inflammatory chemicals facilitate the production of the metalloproteinase (MP) enzyme in the inflammatory and fibroblast cells. In the case of wound recovery, MP can clear the injured site and extracellular matrixes from dead cellular particles and growth factors that aid in wound tissue restoration. However, the prolonged production of pro-inflammatory cytokines and their accumulation in skin tissues cause a delay of the inflammatory phase and a delay in the wound repairing process (late wound closure). The increased pro-inflammatory cytokines along with the proteinase enzymes will denaturize the wound tissues consequently becoming chronic wounds. While interleukin 10 as an anti-inflammatory cytokine suppresses the inflammatory process and autoimmune responses, the elevation of IL-10 can have inhibitory action on cellular response toward microorganisms, preventing hemodynamic interruption and lowering further damage to healthy cells.<sup>59</sup> The present detected increased immunomodulatory potentials of DAG represented by decreased TNF-6 and IL-6 levels and increased IL-10 levels in the serum of rats received 0.2 mL of 250 and 500 mg/kg DAG, which might be due to its increased flavonoid chemical contents as previously reported.<sup>21,60,61</sup> Similarly, researchers have shown the anti-inflammatory action of *D. aucheri* extracts (200 mg/kg/day) in cerebral ischemia-reperfusion injury in rats in a 14-day experimental trial.<sup>54</sup> Accordingly, numerous studies have shown a positive linkage between the significant anti-inflammatory potentials of herbal plants with their increased flavonoids.<sup>62–65</sup>

## 5 | CONCLUSION

Overall, our data provide significant scientific evidence for wound repair efficacy of DAG on dorsal neck injury. The toxicity evaluation did not reveal any toxic signs in rats ingested 2 and 5 g/kg of DAG. The results substantiated the folkloric use of DAG upon wound-healing for the first time. The observed wound recovery efficacy of DAG is linked with its phytochemical contents (polysaccharides, phenolic, and flavonoids), as previously reported. The accelerated wound healing process in rats after topical application of DAG is mediated by positive modulation of angiogenesis and neovascularization, tissue antioxidants, immunohistochemical proteins (Bax and HSP 70), HDX (collagen deposition), and inflammatory cytokines. The outcomes present *Dorema aucheri* gum as an effective wound-healing agent and a cheaper alternative to chemical synthetics for wound management. The current study opens new avenues for future investigation, especially concerning the production of a potent formulation for wound healing.

## ACKNOWLEDGMENTS

The authors extend their appreciation to Researchers Supporting Project number (RSP2024R119), King Saud University, Riyadh, Saudi Arabia, for funding this work.

## DATA AVAILABILITY STATEMENT

Further information regarding the present data will be available on request from Ahmed A.j. Jabbar.

## ORCID

Ahmed A.j. Jabbar  <https://orcid.org/0000-0001-9689-4018>

## REFERENCES

- Kaur G, Narayanan G, Garg D, et al. Biomaterials-based regenerative strategies for skin tissue wound healing. *ACS Appl Bio Mater.* 2022;5(5):2069–2106. doi:10.1021/acsabm.2c00035
- Woodby B, Penta K, Pecorelli A, et al. Skin health from the inside out. *Annu Rev Food Sci Technol.* 2020;11:235–254. doi:10.1146/annurev-food-032519-051722
- Fu X. State policy for managing chronic skin wounds in China. *Wound repair Regen.* 2020;28(4):187–192. doi:10.1016/j.cjtee.2022.12.008
- Duran-Padilla M, Serrano-Loyola R, Perez-Garcia A, et al. Tryptophan intrinsic fluorescence from wound healing correlates with re-epithelialization in a rabbit model. *Ski Res Technol.* 2024;30(7):e13834. doi:10.1111/srt.13834
- Zang XL, Gao F, Zhang Z, et al. Synergistic effects of electroactive antibacterial material and electrical stimulation in enhancing skin tissue regeneration: A next-generation dermal wound dressing. *Ski Res Technol.* 2023;29(11):e13465. doi:10.1111/srt.13465
- Hosseinzade S, Nourani H, Kazemi Mehrjerdi H, et al. The effect of hydatid cyst protoscolex somatic antigens on full-thickness skin wound healing in mouse. *Ski Res Technol.* 2024; 30(4):e13685. doi:10.1111/srt.13685
- Osman Mahmud S, Hamad Shareef S, Jabbar AAJ, et al. Green synthesis of silver nanoparticles from aqueous extract of *Tinospora crispa* stems accelerate wound healing in rats. *Int J Low Extrem Wounds.* 153473462211336, Published online November 3, 2022:15347346221133628. doi:10.1177/15347346221133627
- Tang J, Xu J, Xu J, et al. Soluble polyvinylpyrrolidone-based microneedles loaded with *Sanguis draconis* and *Salvia miltiorrhiza* for treatment of diabetic wound healing. *Ski Res Technol.* 2024;30(4):e13671. doi:10.1111/srt.13671
- Jabbar AA, Abdullah FO, Hassan AO, et al. Ethnobotanical, phytochemistry, and pharmacological activity of *Onosma* (Borraginaceae): an updated review. *Molecules.* 2022; 27:8687. doi:10.3390/molecules27248687
- Park KD, Kwack MH, Yoon HJ, et al. Effects of *Siegesbeckia herba* extract against particulate matter 10 (PM(10)) in skin barrier-disrupted mouse models. *Ski Res Technol.* 2024;30(3):e13615. doi:10.1111/srt.13615
- Pieroni A, Ahmed HM, Zahir H. The spring has arrived: Traditional wild vegetables gathered by Yarsanis (Ahl-e Haqq) and Sunni Muslims in Western Hawraman, SE Kurdistan (Iraq). *Acta Soc Bot Pol.* 2017;86(1). doi:10.5586/asbp.3519
- Kawarty AMAMA, Behçet L, Çakılcioglu U. An ethnobotanical survey of medicinal plants in ballakayati (Erbil, north Iraq). *Turk J Botany.* 2020;44(3):345–357. doi:10.3906/bot-1910-39
- Mohammadi T, Moazzeni H, Pirani A, et al. Ethnobotany of plants used by indigenous communities in Birjand, a dry region with rich local traditional knowledge in eastern Iran. *Ethnobot Res Appl.* 2023;26:1–40. doi:10.32859/era.26.21.1-40
- Mottaghipisheh J, Vitalini S, Pezzani R, et al. A comprehensive review on ethnobotanical, phytochemical and pharmacological aspects of the genus *Dorema*. *Phytochem Rev.* 2021;20(5):945–989. doi:10.1016/j.fitote.2023.105666
- Ajani Y, Claßen-Bockhoff R. The unique inflorescence structure of *Dorema aucheri* (Apiaceae): an adaptation to the arid environment. *J Arid Environ.* 2021;184:104194. doi:10.1016/j.jaridenv.2020.104194

16. Ajani Y, Bockhoff RC. Ethnobotanical interviews on *Dorema aucheri* Boiss. (Apiaceae), a medicinal species in southern Iran. *Int J Env Sci Nat Res*. 2018;12(1):555827. doi: [10.19080/IJESNR.2018.12.555827](https://doi.org/10.19080/IJESNR.2018.12.555827)
17. Sevin G, Alan E, Demir S, et al. Comparative evaluation of relaxant effects of three prangos species on mouse corpus cavernosum: Chemical characterization and the relaxant mechanisms of action of *P. pabularia* and (+)-oxypeucedanin. *J Ethnopharmacol*. 2022;284:114823. doi: [10.1016/j.jep.2021.114823](https://doi.org/10.1016/j.jep.2021.114823)
18. Zibae E, Amiri MS, Boghrati Z, et al. Ethnomedicinal uses, phytochemistry and pharmacology of *Dorema* species (Apiaceae): a review. *J pharmacopuncture*. 2020;23(3):91-123. doi: [10.3831/KPI.2020.23.3.91](https://doi.org/10.3831/KPI.2020.23.3.91)
19. Raesdana A, Farzaei MH, Amini M, et al. Chemical composition of essential oil and evaluation of acute and sub-acute department of traditional pharmacy, school of traditional medicine, tehran, iran . 2 pharmaceutical sciences Faculty of Pharmacy, Tehran University of Medical Sciences, Tehra. *Afr J Tradit Complement Altern Med*. 2018;15(1):26-33. doi: [10.21010/ajtcam.vi15.1.3](https://doi.org/10.21010/ajtcam.vi15.1.3)
20. Mianabadi M, Hoshani M, Salmanian S. Antimicrobial and anti-oxidative effects of methanolic extract of *Dorema aucheri* Boiss. *TT - mdrsjrns*. 2015;17(3):623-634. doi: [10.13140/RG.2.1.5100.1442](https://doi.org/10.13140/RG.2.1.5100.1442)
21. Arabjafari S, Golkar P, Tarkesh Esfahani M, et al. Secondary metabolites and antioxidant activity in different Iranian accessions of *Dorema ammoniacum* D. Don and *Dorema aucheri* Boiss. *J Med Plants By-product*. Published online 2023;12(4):459-468. doi: [10.22092/jmpb.2022.357460.1445](https://doi.org/10.22092/jmpb.2022.357460.1445)
22. Akbarian A, Rahimmalek M, Sabzalian MR. Variation in essential oil yield and composition of *Dorema aucheri* Boiss., an endemic medicinal plant collected from wild populations in natural habitats. *Chem Biodivers*. 2016;13(12):1756-1766. doi: [10.1002/cbdv.201600160](https://doi.org/10.1002/cbdv.201600160)
23. Masoudi S, Esmaeili A, Ali khalilzadeh M, et al. Volatile constituents of *Dorema aucheri* Boiss., *Seseli libanotis* (L.) W. D. Koch var. *armeniacum* Bordz. and *Conium maculatum* L. three Umbelliferae herbs growing wild in Iran. *Flavour Fragr J*. 2006; 21(5):801-804. <https://doi.org/10.1002/ffj.1722>
24. Mahdavi Gourabi A, Ostad Rahimi A, Sadeghi H, et al. The Anti-breast tumors effects of *Dorema aucheri* plant (Bilhar plant) extract, margins of Zagros Mountains in Iran. *Vitae Columbia*. 2014;21:278-284. doi: [10.13140/RG.2.1.1020.6161](https://doi.org/10.13140/RG.2.1.1020.6161)
25. Eftekhari M, Oskou F, Tofighi Z, et al. Alert for consumption of *Dorema aucheri*: an edible medicinal plant of Iran *TT. jmpir*. 2019; 18(71):77-84. doi: [10.29252/jmp.3.71.77](https://doi.org/10.29252/jmp.3.71.77)
26. Henderson VC, Kimmelman J, Fergusson D, et al. Threats to validity in the design and conduct of preclinical efficacy studies: a systematic review of guidelines for in vivo animal experiments. *PLoS Med*. 2013;10(7):e1001489. doi: [10.1371/journal.pmed.1001489](https://doi.org/10.1371/journal.pmed.1001489)
27. Guideline O. 423: Acute Oral Toxicity-Acute Toxic Class Method. OECD Guidelines for the Testing of Chemicals. OECD Publishing; 2001.
28. Jabbar AAJ, Mothana RA, Ameen Abdulla M, et al. Mechanisms of anti-ulcer actions of *Prangos pabularia* (L.) in ethanol-induced gastric ulcer in rats. *Saudi Pharm J*. 2023;31(12):101850. doi: [10.1016/j.jsps.2023.101850](https://doi.org/10.1016/j.jsps.2023.101850)
29. Ahmed KAA, Jabbar AAJ, Galali Y, et al. Cumin (*Cuminum cyminum* L.) seeds accelerates wound healing in rats: possible molecular mechanisms. *Ski Res Technol*. 2024;30(5):e13727. doi: [10.1111/srt.13727](https://doi.org/10.1111/srt.13727)
30. Jabbar AA j, Abdul-Aziz Ahmed K, Abdulla MA, et al. Sinomenine accelerate wound healing in rats by augmentation of antioxidant, anti-inflammatory, immunohistochemical pathways. *Heliyon*. 2024;10(1):e23581. doi: [10.1016/j.heliyon.2023.e23581](https://doi.org/10.1016/j.heliyon.2023.e23581)
31. Jabbar AA j., Alamri ZZ, Abdulla MA, et al. Hepatoprotective effects of *Gynura procumbens* against thioacetamide-induced cirrhosis in rats: targeting inflammatory and oxidative stress signalling pathways. *Heliyon*. 2023;9(9):e19418. <https://doi.org/10.1016/j.heliyon.2023.e19418>
32. Mariod AA, Jabbar AAJ, Alamri ZZ, et al. Gastroprotective effects of *Polygonatum odoratum* in rodents by regulation of apoptotic proteins and inflammatory cytokines. *Saudi J Biol Sci*. 2023;30(6):103678. doi: [10.1016/j.sjbs.2023.103678](https://doi.org/10.1016/j.sjbs.2023.103678)
33. Mustafa MR, Mahmood AA, Salmah I. Effects of *Trigonella foenum-graecum* seed extract in combination with honey on experimental wound healing in rats. *Int J Mol Med Adv Sci*. 2005;1(1):243-254. doi: [10.3109/13880209.2013.826247](https://doi.org/10.3109/13880209.2013.826247)
34. Bagheri E, Saremi K, Hajiaghaalipour F, et al. Synthesis of novel derivatives of quinazoline Schiff base compound promotes epithelial wound healing. *Curr Pharm Des*. 1395-1404, 2018;24(13). doi: [10.2174/1381612824666180130124308](https://doi.org/10.2174/1381612824666180130124308)
35. Hama Amin RR, Aziz TA. Gastroprotective effect of azilsartan through ameliorating oxidative stress, inflammation, and restoring hydroxyproline, and gastrin levels in ethanol-induced gastric ulcer. *J Inflamm Res*. 2022;15:2911-2923. doi: [10.2147/JIR.S365090](https://doi.org/10.2147/JIR.S365090)
36. Mojarradgandoukmolla S, Nanakali NMQ, Abjabbar A. Hypolipidemic and anti-oxidative activities of *Terminalia arjuna* barks against induced hyperlipidemic albino rats. *Plant Arch*. 2021;21(1):2082-2086. doi: [10.51470/plantarchives.2021.v21.s1.343](https://doi.org/10.51470/plantarchives.2021.v21.s1.343)
37. Ahmed KAA, Jabbar AAJ, MRaouf MMH, et al. Wood calamint ameliorates ethanol-induced stomach injury in rats by augmentation of hsp/bax and inflammatory mechanisms. *J Mol Histol*. Published online 2024. doi: [10.1007/s10735-024-10211-7](https://doi.org/10.1007/s10735-024-10211-7)
38. Wahab BAA, Alamri ZZ, Jabbar AA j., et al. Phytochemistry, antioxidant, anticancer, and acute toxicity of traditional medicinal food *Biarum bovei* (Kardeh). *BMC Complement Med Ther*. 2023;23(1):283. doi: [10.1186/s12906-023-04080-y](https://doi.org/10.1186/s12906-023-04080-y)
39. Ajani Y, Bockhoff RC. Ethno botanical interviews on *Dorema Aucheri* Boiss . (Apiaceae), a medicinal species in Southern Iran. *Int J Environ Sci Nat Resour*. 2018;12(1):555827. doi: [10.19080/IJESNR.2018.12.555827](https://doi.org/10.19080/IJESNR.2018.12.555827)
40. Ahangarpour A, Oroojan AA, Heydari H. Effect of hydro-alcoholic extract of *Dorema Aucheri* on serum levels of testosterone, FSH and sperm count in nicotinamide-STZ-induced diabetic rat models. *J Zanjan Univ Med Sci Heal Serv*. 2013;21(87).
41. Ahangarpour A, Zamaneh HT, Jabari A, et al. Antidiabetic and hypolipidemic effects of *Dorema aucheri* hydroalcoholic leave extract in streptozotocin-nicotinamide induced type 2 diabetes in male rats. *Iran J Basic Med Sci*. 2014;17(10):808.
42. Nejaddehbashi F, Rafiee Z, Orazizadeh M, et al. Antibacterial and antioxidant double-layered nanofibrous mat promotes wound healing in diabetic rats. *Sci Rep*. 2023;13(1):3166. doi: [10.1038/s41598-023-30240-8](https://doi.org/10.1038/s41598-023-30240-8)
43. Sen CK. Human wound and its burden: updated 2020 Compendium of Estimates. *Adv Wound Care*. 2021;10(5):281-292. doi: [10.1089/wound.2021.0026](https://doi.org/10.1089/wound.2021.0026)
44. Gautam A, Kumar V, Azmi L, et al. Wound healing activity of the flavonoid-enriched fraction of *Selaginella bryopteris* Linn. against Streptozocin-induced diabetes in rats. *Separations*. 2023;10(3):166. doi: [10.3390/separations10030166](https://doi.org/10.3390/separations10030166)
45. Mohammed SM, Taqa GA, Sulaiman MS. Effect of flavonoid luteolin on primary oral wound healing in rats. In: *AIP Conference Proceedings*. Vol 2547. AIP Publishing; 2022. doi: [10.1063/5.0113495](https://doi.org/10.1063/5.0113495)
46. Siahpoosh A, Malayeri A, Salimi A, et al. Determination of the effectiveness of *Dorema ammoniacum* gum on wound healing: an experimental study. *J Wound Care*. 2022;31(Sup10):S16-S27. doi: [10.12968/jowc.2022.31.Sup10.S16](https://doi.org/10.12968/jowc.2022.31.Sup10.S16)
47. Abdevand ZZ, Siahpoosh A, Malayeri A, et al. Determination the effectiveness of a selected formulations of Iranian traditional medicine“ Ushaq poultice”(ammoniacum gum ointment) on wound healing: An experimental study. *J Contemp Med Sci*. 39-49, 2020;6(2). doi: [10.22317/jcms.v6i2.719](https://doi.org/10.22317/jcms.v6i2.719)
48. Jabbar AAJ, Alamri ZZ, Abdulla MA, et al. Boric acid (Boron) attenuates AOM-induced colorectal cancer in rats by augmentation of apoptotic

- and antioxidant mechanisms. *Biol Trace Elem Res.* 2702-2719, Published online 2023. doi:10.1007/s12011-023-03864-0
49. Jabbar AAJ, Alamri ZZ. Acute toxicity and hepatoprotective influence of *Hypericum perforatum* against thioacetamide-induced liver fibrosis in rats. *Nat Prod Commun.* 2024;19(5):1934578X241250243. doi:10.1177/1934578x241250243
  50. Gan C, Liu T, Jia X, et al. ATP supplementation suppresses UVB-induced photoaging in HaCaT cells via upregulation of expression of SIRT3 and SOD2. *Ski Res Technol.* 2023;29(3):e13303. doi:10.1111/srt.13303
  51. Ali Abed Wahab B, Ain Salehen N, Abdulla MA, et al. Pinosrobin attenuates azoxymethane-induced colorectal cytotoxicity in rats through augmentation of apoptotic Bax/Bcl-2 proteins and antioxidants. *SAGE Open Med.* 2023;11:20503121231216584. doi:10.1177/20503121231216585
  52. Moawad H, El Awdan SA, Sallam NA, et al. Gastroprotective effect of cimetidine against ethanol- and pylorus ligation-induced gastric lesions in rats. *Naunyn Schmiedeberg's Arch Pharmacol.* 1605-1616, 2019;392(12). doi:10.1007/s00210-019-01699-y
  53. Li S, Shao L, Fang J, et al. Hesperetin attenuates silica-induced lung injury by reducing oxidative damage and inflammatory response. *Exp Ther Med.* 2021;21(4):297. doi:10.3892/etm.2021.9728
  54. Gupta P, Sheikh A, Abourehab MAS, et al. Amelioration of full-thickness wound using hesperidin loaded dendrimer-based hydrogel bandages. *Biosensors.* 2022;12(7):462. doi:10.3390/bios12070462
  55. Rasouli Vani J, Taghi Mohammadi M, Sarami Foroshani M, et al. Evaluation of the neuroprotective and antioxidant effects of *Dorema aucheri* extract on cerebral ischaemia-reperfusion injury in rats. *Pharm Biol.* 2019;57(1):255-262. doi:10.1080/13880209.2019.1597132
  56. Ahmadi E, Rezadoost H, Alilou M, et al. Purification, structural characterization and antioxidant activity of a new arabinogalactan from *Dorema ammoniacum* gum. *Int J Biol Macromol.* 2022;194:1019-1028. doi:10.1016/j.ijbiomac.2021.11.163
  57. Talbott HE, Mascharak S, Griffin M, et al. Wound healing, fibroblast heterogeneity, and fibrosis. *Cell Stem Cell.* 2022;29(8):1161-1180. doi:10.1016/j.stem.2022.07.006
  58. Alkreathy HM, Esmat A. Lycorine ameliorates thioacetamide-induced hepatic fibrosis in rats: emphasis on antioxidant, anti-inflammatory, and STAT3 inhibition effects. *Pharmaceuticals.* 369, 2022;15(3). doi:10.3390/ph15030369
  59. Wolf SJ, Melvin WJ, Gallagher K. Macrophage-mediated inflammation in diabetic wound repair. In: *Seminars in Cell & Developmental Biology.* Vol 119. Elsevier; 2021:111-118. doi:10.1016/j.semcdb.2021.06.013
  60. Abdul-Aziz Ahmed K, Jabbar AAJ, Abdulla MA, et al. Mangiferin (mango) attenuates AOM-induced colorectal cancer in rat's colon by augmentation of apoptotic proteins and antioxidant mechanisms. *Sci Rep.* 2024;14(1):813. doi:10.1038/s41598-023-50947-y
  61. Hossiniyan SA, Latifpour M, Mohammadi B, et al. Chemical composition and cytotoxic activity of the essential oil from the aerial parts of *Dorema aucheri*. *J Herbmed Pharmacol.* 2021;10(3):344-350. doi:10.34172/jhp.2021.40
  62. Arabjafari S, Golkar P, Esfahani MT, et al. Composition of the essential oil of different plant organs in *Dorema ammoniacum* D. Don and *Dorema aucheri* Boiss. accessions collected from Iran. *Nat Prod Res.* 2023;37(13):2298-2302. doi:10.1080/14786419.2022.2037086
  63. Maleki SJ, Crespo JF, Cabanillas B. Anti-inflammatory effects of flavonoids. *Food Chem.* 2019;299:125124. doi:10.1016/j.foodchem.2019.125124
  64. Hussain T, Murtaza G, Yang H, et al. Exploiting anti-inflammation effects of flavonoids in chronic inflammatory diseases. *Curr Pharm Des.* 2020;26(22):2610-2619. doi:10.2174/1381612826666200408101550
  65. Almainani G, Jabbar AAJ, Ibrahim IAA, et al. Anise (*Pimpinella anisum* L.) attenuates azoxymethane-induced colorectal cancer by antioxidant, anti-inflammatory, and anti-apoptotic pathways in rats. *Environ Sci Pollut Res.* 4439-4452, Published online 2023. doi:10.1007/s11356-023-31349-z

**How to cite this article:** Ahmed KAA, Jabbar AAJ, Raouf MMHM, et al. A bitter flavonoid gum from *Dorema aucheri* accelerate wound healing in rats: Involvement of Bax/HSP 70 and hydroxyprolin mechanisms. *Skin Res Technol.* 2024;30:e13896. <https://doi.org/10.1111/srt.13896>